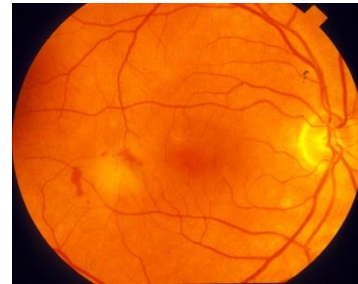


## Metamorphopsia and ARMD

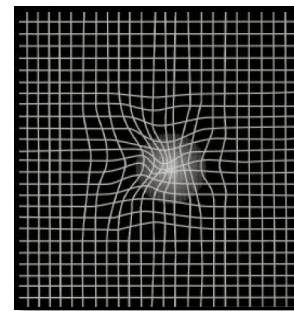
Early detection and intervention are important to prevent or delay vision loss in age related macular degeneration (ARMD).

Retinal metamorphopsia occur in the early stage of ARMD as a result of elevations of the pigment epithelium.



These metamorphopsia are usually evaluated with the Amsler chart.

However, this test suffers from several limitations including the difficulty of self-reporting, the absence of fixation monitoring, the absence of quantification and problems with filling-in phenomenon.



1/2

## Methodology

This program provides an automated detection of metamorphopsia and the follow-up of their evolution.

It is designed to overcome the problems encountered with the Amsler chart:

The test is similar to a perimetry test. Local patterned stimuli are presented in a pseudo random sequence and the patient task is to press a button whenever the pattern is perceived without distortion.

The program starts with a training phase. The following examination phase includes 31 different test locations.

An additional phase can be added for 16 additional locations. The test duration is about 90 seconds for the first phase including controls for attention and fixation errors.

The complete test duration, including the second examination phase is about 150 seconds.

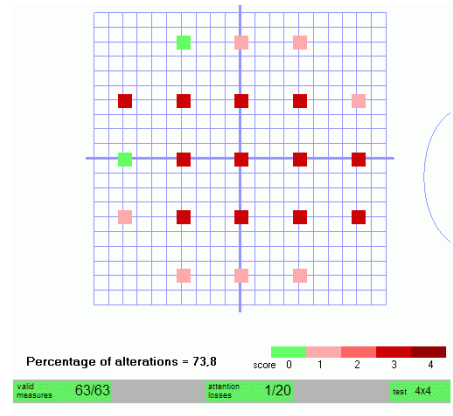


This program is available on the Moncv3 and MonPack multifunction Vision Monitor systems.

These systems include a built-in fixation monitoring device. A standard PC operating under Windows is used for the control of the instrument as well as for the storage and printout of results.

## Quantitative analysis

The program provides a standardized report including a map of probability of altered locations and the total percentage of locations with alterations.



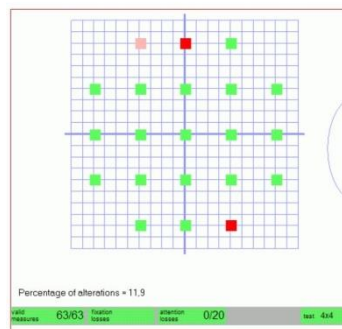
## Comparison with the eye fundus

The program allows the comparison of the metamorphopsia with the eye fundus.

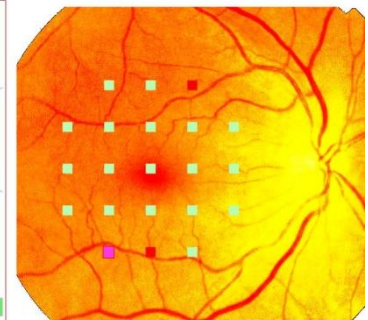
The image of the eye fundus is imported as an image file either through the computer network or by USB key, CDROM etc.

The operator identifies by a simple click the position of the fovea and papilla and the program automatically performs the scaling and repositioning the eye fundus image.

Mme LE, 68 years OD (XZ)



Cartography of metamorphopsias



Superposition with eye fundus

2/2

Compatible stimulators: **MonCV3** **MonPack** *One*

## References

- INAN U.U. & al Metamorphopsia increases in patients with early dry age-related macular degeneration. Euroretina Congress presentation. 2014.
- PARK S.Y. & al Correlation between degree of metamorphopsia and optical coherence tomography findings in epiretinal membrane. ARVO meeting Poster C0128 2016.