

Scene Perception in Age-Related Macular Degeneration

Thi Ha Chau Tran,^{1,2} Camille Rambaud,² Pascal Despretz,¹ and Muriel Boucart¹

PURPOSE. To assess the scene gist recognition in eyes with age-related macular degeneration (AMD) and to study the relationship between scene recognition and macular function.

METHODS. Twenty-seven patients with age-related macular degeneration with a visual acuity lower than 20/50 and 17 age-matched controls were included. All patients underwent a visual field test, fundus autofluorescence, and fluorescein angiography to assess the visual field defect and the lesion size. The stimuli were colored photographs of natural scenes displayed on a 30-inch screen. Two scene categorization tasks were performed: natural versus urban and indoor versus outdoor scenes. Participants were given a target (e.g., indoor scenes) and asked to press a key when they saw a picture corresponding to that target. Accuracy and response times were recorded.

RESULTS. Patients with AMD were able to accomplish both categorization tasks with a high correct detection rate (above 75% correct), though performance was lower than in controls for both natural/urban scenes and indoor/outdoor scenes. Patients with AMD were more accurate and faster for natural/urban scenes than for indoor/outdoor scenes, but performance did not differ between the two categories in controls. No significant correlation was found between performance for scene categorization and clinical variables such as visual acuity, type of AMD, size of the scotoma, and size of the lesion.

CONCLUSIONS. Scene gist recognition can be accomplished with the low spatial resolution of peripheral vision. These results support the “scene-centered approach” that initial scene recognition is based on the global scene properties and not on the objects it contains. (*Invest Ophthalmol Vis Sci.* 2010;51:6868–6874) DOI:10.1167/iovs.10-5517

Age-related macular degeneration (AMD) is the leading cause of legal blindness among the elderly in industrialized countries.¹ Vision loss, in its late stage, is a consequence of one of two processes that cause photoreceptor dysfunction: geographic atrophy (dry AMD) or choroidal neovascularization (neovascular or wet AMD).

AMD affects the region with the highest density of photoreceptors: the macula, approximately 6 mm in diameter, covering the central 15–20° of the visual field. At late stages, once

the spatial resolution of the fovea cannot be used and fixation is controlled, a preferred retinal location is developed.² It is known that central vision is responsible for resolving fine details and that peripheral vision plays a role in spatial orientation and locomotion.³ Previous publications on vision-related quality of life in patients with AMD report difficulties in performing vision-related daily tasks, such as reading, writing, cooking, and driving, leading to a progressive loss of independence and decreased related functions.^{4,5} Patients with AMD also encounter more difficulties than do age-matched, normally sighted individuals when shopping (finding objects on shelves), managing money, preparing meals, performing light housework, and recognizing facial expressions and pictures, especially when the illumination level is low and during the transition from bright to dim illumination.⁶ These questionnaires suggest impaired object and scene recognition in patients with AMD.

In contrast to reading^{7–9} and face recognition,^{10–12} few investigations have been devoted to the deleterious impact of central vision loss on object and scene perception.^{12,13} Since central and peripheral vision serve different purposes—for instance, neuroimaging studies have shown that objects requiring large-scale feature integration (such as buildings) activate regions of the visual cortex corresponding to peripheral vision whereas objects requiring finer analysis (faces, words) are associated with center-biased representations^{14–16}—it is interesting to understand how patients with central vision loss recognize natural scenes.

Studies on normally sighted young participants have shown that observers recognize a real-world scene at a single glance. In less than 100 ms the visual system forms a spatial representation of the world that is rich enough to grasp the meaning of the scene, recognizing some objects and other salient information.^{17,18} This representation refers to the *gist of a scene*.¹⁹ It includes all levels of processing, from low-level features (color, orientations, spatial frequencies, etc.) to intermediate image properties (surfaces, volumes) and high-level information (objects, contextual and semantic knowledge, familiarity, etc.).

The question of the contribution of central versus peripheral vision in scene gist recognition was recently addressed in normally sighted young people by Larson and Loschky.²⁰ Participants were presented with photographs of real-world scenes (27° × 27° of visual angle) for 106 ms. Each scene was followed by a name (e.g., river). Participants were asked to decide if the scene matched the name. Performance was compared in two conditions: a window condition showing the central portion of the scene and blocking peripheral information, and a scotoma condition blocking out the central portion and showing only the periphery. The radii of the window and scotoma were 1°, 5°, 10.8°, and 13.6°. Performance was barely above chance in the 1° window condition, suggesting that foveal vision is not useful for recognizing scene gist. Accuracy increased as the radius of the window increased. Conversely, when participants had information from everything but not foveal vision (in the 1° scotoma condition), performance was equal to seeing the entire image. Based on these data, the authors suggested that peripheral (and parafoveal vision) is

From the ¹Laboratoire de Neurosciences et Pathologies Fonctionnelles, CNRS, Université Lille Nord de France, Lille, France; and the ²Service d’Ophtalmologie, Hôpital Saint Vincent de Paul, Lille, France.

Presented in part at the annual meeting of the Vision Science Society, Naples, Florida, May 2009.

Supported by a grant from the Programme Interdisciplinaire “longévité-vieillesse” by the Centre National de la Recherche Scientifique (MB).

Submitted for publication March 11, 2010; revised July 2, 2010; accepted July 3, 2010.

Disclosure: T.H.C. Tran, None; C. Rambaud, None; P. Despretz, None; M. Boucart, None

Corresponding author: Muriel Boucart, CHRU Lille, Hôpital Roger Salengro, Laboratoire Neurosciences et Pathologies Fonctionnelles, 59037 Lille, France; m-boucart@chru-lille.fr.

more useful than high-resolution foveal vision for scene gist recognition.

In the present study, we assessed whether scene gist recognition can be accomplished by low-resolution peripheral vision in people with central vision loss. We compared performance for two spatial properties corresponding to different levels of scene analysis: a categorization based on naturalness (natural versus urban scenes) and a categorization in terms of indoor versus outdoor scenes. Though these two properties are considered as holistic or global (i.e., the categorization can be based on the overall layout),¹⁸ studies on young normally sighted observers have shown longer categorization times (around 470 ms) for indoor versus outdoor scenes than for naturalness (around 390 ms),^{21,22} likely because a more local (object) analysis is required to discriminate between indoor and outdoor scenes whereas a coarse perception based on orientation and color is sufficient to decide if a scene is natural or urban. As central vision is involved in fine perception and information is more coarsely encoded in the periphery, we expected patients with AMD to be more impaired in the indoor/outdoor categorization task than for naturalness. Second, we investigated the correlation between visual acuity, scotoma size, lesion size, and performance for scene categorization.

METHODS

Participants

Patients with AMD. Twenty-seven patients with a confirmed diagnosis of AMD were recruited. Inclusion and exclusion criteria are summarized in Table 1. Only one eye of each patient was studied. In cases of bilateral AMD, we considered the eye with the best corrected visual acuity. If both eyes had equal acuity, one eye was randomly selected.

Controls. The age-matched healthy controls consisted of 17 volunteers. The control participants had no history of ophthalmologic or neurologic diseases and no cognitive impairment. Control participants were either relatives of participants with AMD or patients who have had successful cataract surgery with noncorrected visual acuity ranging from 20/25 to 20/20. Controls were tested monocularly on their preferred eye.

Both participants with AMD and controls were recruited from March 2009 to January 2010 in the Ophthalmology Department of Saint Vincent de Paul Hospital, Lille, France. The study was approved by the ethics committee of Lille, in accordance with the tenets of the Declaration of Helsinki. Written informed consent was obtained from all participants.

Clinical Examination

Ophthalmologic Examination. Best corrected visual acuity was determined using early treatment diabetic retinopathy study charts

at a distance of 4 m, which was converted to logMAR visual acuity for statistical purposes. Slit lamp examination, intraocular pressure, and funduscopy were performed in all patients and controls.

Imaging Studies and Lesion Size Measurement. Fundus autofluorescence was performed in atrophic AMD and fluorescein angiography in neovascular AMD, using a confocal scanning laser ophthalmoscope (Heidelberg Retina Angiograph, HRA2; Heidelberg Engineering, Dossenheim, Germany). The optical and the technical principles of this have been described previously.^{23,24} The area of geographic atrophy (mm^2) was measured by outlining dark atrophic areas using image analysis software (Heidelberg Eye Explorer; Heidelberg Engineering).

The diagnosis of neovascular AMD was confirmed by fluorescein angiography. The entire complex component (choroidal neovascularization, elevated blocked fluorescence, thick blood) is considered to constitute the neovascular lesion. Lesion components also included contiguous flay-blocked fluorescence, fibrous tissue, and thin flat scars. The area of the lesion (mm^2) was measured from digital angiograms by outlining the lesion, using image analysis software (Heidelberg Eye Explorer).

Visual Field Test. Central and peripheral visual fields were assessed using an evaluation program (Mix-30 with Vision Monitor; Metrovision, Lille, France). This program combines the evaluation of the peripheral visual field with the kinetic perimetry to the evaluation of the central field with the FAST perimetry (94 points) (more technical details can be found at <http://metrovision.fr>).

The test luminance of central and intermediate isopters was adjusted automatically to obtain responses at 30° and 15° eccentricity. Eight additional measurements were used to determine the blind spot contour. The stimulus was displaced at a constant velocity of 10° per second for the peripheral isopter, 5° per second for the intermediate, and 2° per second for the central isopter and the blind spot contour. Fixation was monitored throughout the examination with an infrared camera.

Only visual field tests with <2 losses of fixation were used for statistical analysis. The volume of sensitivity loss (dB/deg^2), computed by the software described above, was used to measure visual field deficit. Clinical assessment and experiments were scheduled within 1 week.

Experiments

Stimuli. The stimuli were photographs of natural scenes. Two scene properties were selected: naturalness (natural versus urban scenes) and indoor/outdoor scenes. Examples are shown in Figure 1. The angular size of the photographs was 15° × 15° at a viewing distance of 1 m. The participant's head was not fixed.

Apparatus. Pictures were centrally displayed on a 30-inch screen (Dell, Dallas, TX) connected to a computer (T 3400; Dell). Participants responded on a box containing two keys connected to the computer. The software was written by one of the authors (PD) in a general-purpose programming language (C++). People were tested in a dimly

TABLE 1. Inclusion and Exclusion Criteria for AMD Participants

Inclusion criteria	
Willing to give informed consent	
Clinical diagnosis of atrophic AMD or neovascular AMD well defined with subfoveal involvement confirmed by fluorescein angiography	
Best corrected visual acuity between 20/40 and 20/400 in the eye to be studied	
Refraction between +3 D and -3 D	
Exclusion criteria	
History of any neurological or psychiatric disease	
History of ophthalmologic disease other than AMD that might compromise its visual acuity or peripheral vision during the study (amblyopic, uncontrolled glaucoma, optic neuropathy, diabetic retinopathy, uveitis)	
Unable to communicate (deafness)	
Treated with medication that might compromise concentration (benzodiazepine, narcoleptics)	
Mental deterioration with MMSE < 24	

MMSE, Mini-Mental State Examination.

Natural



Urban



Indoor



Outdoor



FIGURE 1. Examples of photographs used in the natural/urban categorization task and in the indoor/outdoor categorization task.

illuminated room. The luminance of the gray background was 56 cd/m², measured by a photometer (CS 100; Minolta, Paris, France).

Procedure. A black fixation cross (5°) was centrally displayed for 500 ms and followed by a single photograph of a scene centrally displayed for 300 ms. This duration was long enough for the patients to perceive it but short enough to allow a single fixation.

Participants were given a target for each categorization task. For naturalness, urban scenes were chosen as target for half of the participants and natural scenes for the other half of the participants. The same procedure was used for indoor/outdoor scenes. A scene appeared every 3 seconds. Participants were asked to press a key as soon as they saw a picture corresponding to the predefined target. There were 100 trials/category: 50 targets (e.g., natural scenes) and 50 distractors (e.g., urban scenes). Participants were given a few trials to familiarize with the exposure duration and the task, usually <20.

Measurements. Responses were recorded on the basis of the signal detection theory²⁵ with correct detections of the target (natural or urban; indoor or outdoor) quoted as hits, detection of a target when there was none quoted as a false alarm, failure to detect the target when it was present quoted as an omission, and no response when the target was absent quoted as correct rejections. Based on these data the *d'* index of sensitivity was computed for each participant for each categorization. Performance was evaluated in terms of hits, false alarms, and response times (RTs).

Statistical Analysis

The differences between groups were assessed by analyses of variance. The between-subject factor was group (controls, patients with AMD). The within-subject factor was the type of categorization (natural/urban scenes and indoor/outdoor scenes).

Correlations between parameters of performance (hits, false alarms) for each level of categorization and logMAR visual acuity, lesion

size measurement, and size of scotoma were performed by using Pearson's correlation or nonparametric Spearman rank correlation coefficient (*r*) when necessary and the matching significance of the correlation (*P*). Statistical significance is reported as *P* < 0.05. All data were analyzed using statistical software (Statistica, v8; Statsoft, Maisons-Alfort, France).

RESULTS

Demographic and Clinical Data

The demographic details and clinical data of both AMD and control groups are summarized in Table 2. Twenty-seven patients with AMD were included in the study: 10 had dry AMD, and 17 had neovascular AMD. The mean age was 79 years, ranging from 59 to 91. The mean logMAR visual acuity was

TABLE 2. Demographic and Clinical Data of the Study Population

AMD participants, <i>n</i>	27
Age in years, mean ± SD (range)	79 ± 7.5 (59–91)
Sex, M/F	10/17
MMSE score, mean ± SD	28 ± 1.5
LogMAR VA, mean ± SD	0.9 ± 0.3
Lesion size in mm ² , mean ± SD (range)	13.4 ± 14 (1.46–52)
Loss of sensitivity in dB/deg ² , mean ± SD (range)	806 ± 483 (91–1492)
Controls, <i>n</i>	17
Age in years, mean ± SD	74 ± 8.5
Sex, M/F	4/13
LogMAR VA, mean ± SD	0.03 ± 0.04
MMSE score, mean ± SD	29.5 ± 1.1

MMSE, Mini-Mental State Examination.

0.9 ± 0.3 (approximate Snellen visual acuity 20/100). The size of the lesion was variable, ranging from 1.46 to 15 mm^2 with a mean size of $13.4 \pm 14 \text{ mm}^2$. In dry AMD the mean surface of atrophy was 19 mm^2 , and in neovascular AMD the mean surface of the lesion was 10.5 mm^2 . The mean greatest diameter of the lesion in neovascular AMD was 3.7 mm , corresponding to a central scotoma of approximately 12° of visual angle.²

Central and peripheral visual fields were available in 24/27 patients. Examples are shown in Figure 2. In three patients, visual field measurement was not possible because of fatigue and poor vision (20/400) and multiple loss of fixation during the test. No patient exhibited constriction of the peripheral isopter. They responded to the test luminance (310 cd/m^2) at least 60° temporally, 45° nasally, 30° superiorly, and 45° inferiorly. FAST perimetry revealed a central scotoma in all patients, which included absolute (deficit above 20 dB) and relative scotoma (loss of sensitivity) in 20/24 eyes. Relative scotoma was found in 4/24 eyes. The scotoma were recorded

eccentrically in four patients, because of new preferred retinal locations. Perimetric results can be considered as valid if interpretation accounts for eccentric fixation.²⁶ The absolute scotoma size varied from 5° to 30° of eccentricity. Since the patterns of the scotoma was variable, and macular scotometry based on conventional perimetry has limited accuracy because of unstable fixation,²⁶ the volume of sensitivity loss, computed by software (VisionMonitor Software LLC, Lille, France) was used for statistical purposes.

Results of the Experiments

Performance, in terms of correct detections (hits) and d' index of sensitivity, is displayed in Figure 3.

Scene Category for Both AMD and Controls. Averaged over all participants, there was no significant difference in terms of correct detections (hits) and response times between indoor (606 ms and 85.8% hits) and outdoor (613 ms and 84.8%

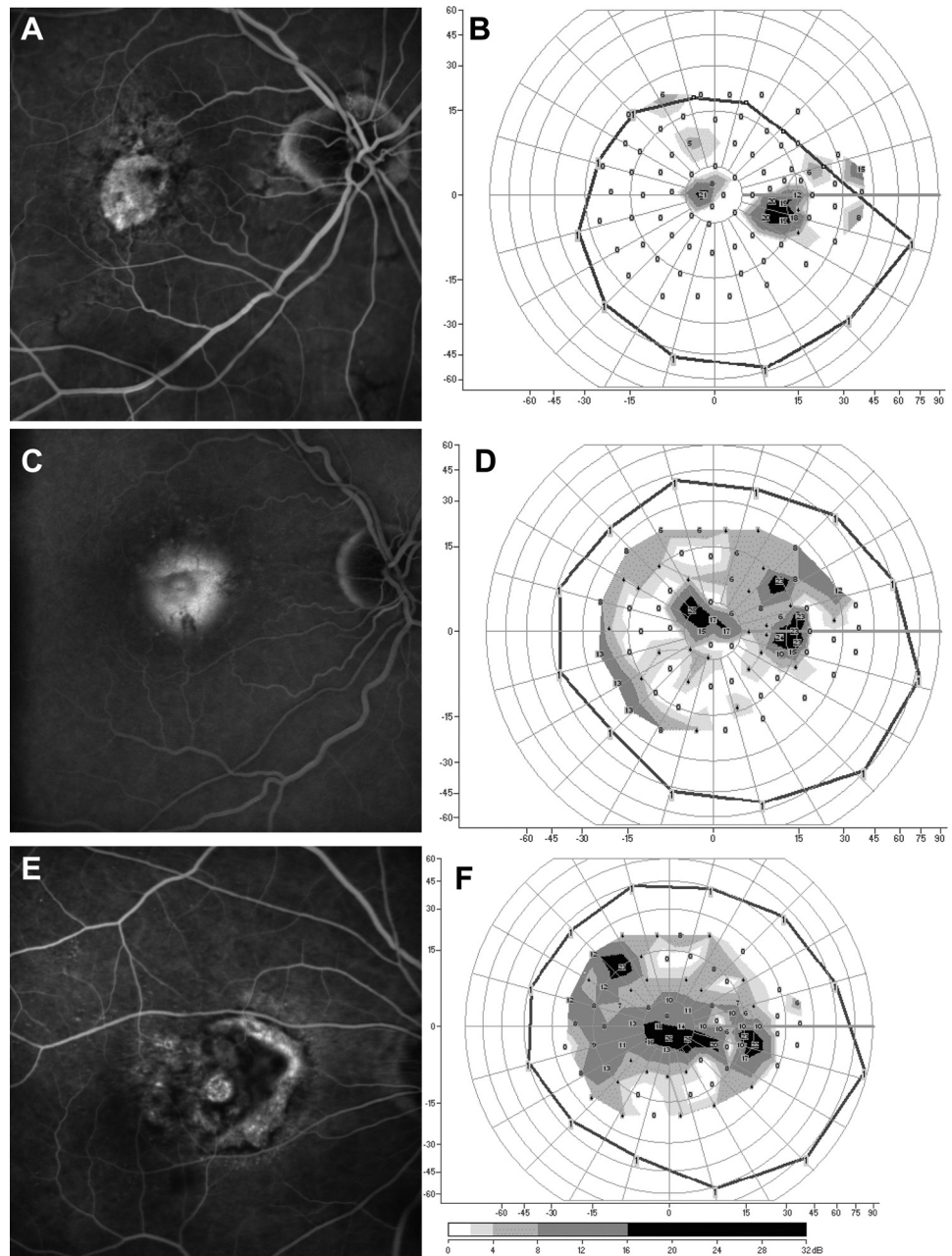


FIGURE 2. Examples of patients. (A, B) Case 1: An 83-year-old woman with inactive neovascular AMD: visual acuity was 20/50, greatest diameter was 2.1 mm, surface of the lesion was 3.5 mm^2 , the approximate of the absolute scotoma area was $5^\circ \times 5^\circ$, and the volume of sensitivity loss was 91 dB/deg^2 . Correct detections (hit) rate was 68% in indoor/outdoor categorization and 70% in naturalness categorization. (C, D) Case 2: A 75-year-old man with neovascular AMD had high performance in both level categorization (hit rate of 98% in indoor/outdoor and 100% in natural/urban categorization) although a low vision (visual acuity = 20/400), lesion diameter was 2.5 mm, surface of the lesion was 3.6 mm^2 , the approximate size of the absolute scotoma was $10^\circ \times 5^\circ$, and the volume of sensitivity loss was 288 dB/deg^2 . (E, F) Case 3: An 80-year-old man with better correct detection rate in naturalness (98%) than in indoor/outdoor (74%) categorization. His visual acuity was 20/200, greatest diameter was 3.5 mm, surface of the lesion was 7.9 mm^2 , the approximate of the absolute scotoma area was $15^\circ \times 5^\circ$, and the volume of sensitivity loss was 531 dB/deg^2 .

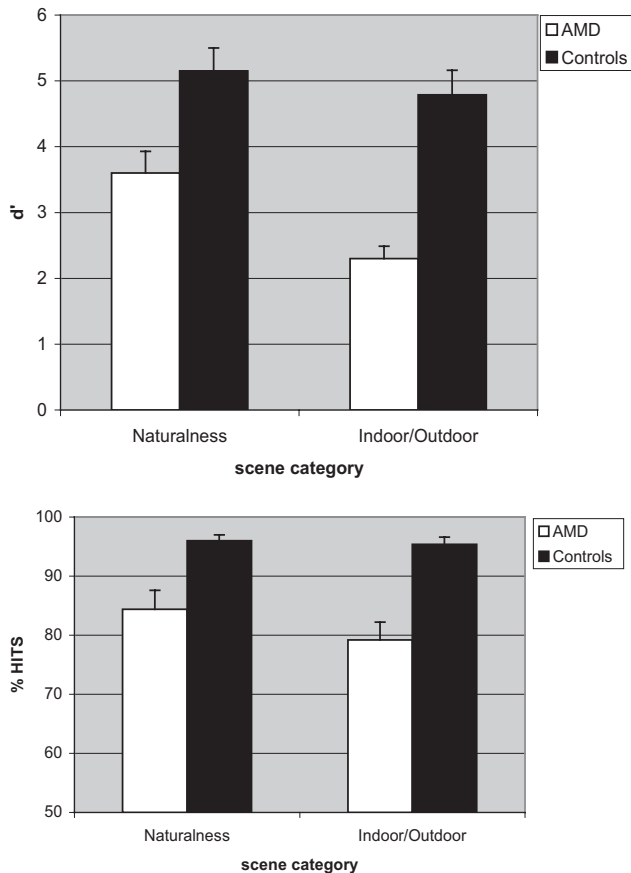


FIGURE 3. Top: the d' index of sensitivity. Bottom: The percentage of correct detections (hits) as a function of the group (patients with AMD versus controls) and the categorization task (natural/urban versus indoor/outdoor).

hits) scenes. For naturalness, urban scenes were categorized faster and more accurately than natural scenes (523 ms and 91.8% vs. 586 ms and 86.6%), but the differences were not statistically significant ($F_{(1,42)} = 1.3$ ns for hits and $F_{(1,42)} = 2.2$ ns for RTs). This variable did not interact with group. There was no significant difference in performance between the different types of AMD ($F_{(1,25)} = 2.5$, ns) and no interaction between type of AMD and scene category.

Categorization Performance in AMD versus Controls.

The results are summarized in Tables 3 and 4. When both categories (natural/urban and indoor/outdoor) were analyzed together, the hit rate was higher for controls than for patients with AMD (95.7% vs. 81.8%, $F_{(1,42)} = 12.6$, $P < 0.001$). The number of false alarms was higher for patients with AMD than for controls (9% vs. 3.5%, $F_{(1,42)} = 11.4$, $P < 0.002$). RTs did not differ significantly between the two groups (patients: 596 ms vs. controls 563 ms, $F < 1$). These differences were found for each category when measurements were analyzed separately (Table 3).

Group interacted with category for hits ($F_{(1,42)} = 4.4$, $P < 0.042$) but not for RTs ($F_{(1,42)} = 2.84$, $P < 0.09$). Patients with AMD were more accurate and faster for natural/urban scenes than for indoor/outdoor scenes (84.4% vs. 79.2%, $t_{(26)} = 3.34$, $P < 0.003$, and 565 vs. 628 ms $t_{(26)} = 5.49$, $P < 0.01$) while performance did not differ significantly between the two categories in controls (96% and 95.4%, $t < 1$, and 548 vs. 579 ms, $t_{(16)} = 1.94$, $P = 0.06$). False alarms were higher in the indoor/outdoor category than for natural/urban category in

TABLE 3. Difference in Performance between Groups for Each Scene Category

	AMD Patients	Controls	<i>P</i>
Both Categories Combined			
Hit, %	81.8	95.7	<0.023
Response times, ms	596	563	NS
False alarms, %	9	3.5	<0.002
Natural/Urban			
Hit, %	84.4	96	<0.009
Response times, ms	565	548	NS
False alarms, %	6.4	2	<0.023
Indoor/Outdoor			
Hit, %	79.2	95.4	<0.001
Response times, ms	628	579	NS
False alarms, %	11.6	5	<0.006

NS, not significant.

both groups (AMD: 11.6% vs. 6.4%, $t_{(26)} = 2.79$, $P < 0.01$, and controls: 5% vs. 2%, $t_{(16)} = 2.68$, $P < 0.01$; Table 4).

Sensitivity (measured by the d' of the signal detection theory²⁵ showed a better sensitivity for natural/urban than for indoor/outdoor scenes in people with AMD ($d' = 3.6$ vs. 2.33, $t_{(26)} = 4.59$, $P < 0.01$), but not for controls ($d' = 5.15$ vs. 4.79, $t_{(16)} = 2.29$, $P = 0.35$; Fig. 3).

Relationship between Visual Function, Lesion Size, and Performance of Categorization

There was a correlation between the volume sensitivity loss and response times in the category indoor/outdoor ($r = .47$, $P = 0.03$). No relationship was found between parameters of performance (in terms of hits and d') and clinical data (visual acuity, lesion size, loss of sensitivity in any type of AMD) in indoor/outdoor categorization. No relationship was found between performance (in terms of hits and d') for natural/urban categorization and any clinical data.

DISCUSSION

The purpose of the study was to investigate the role of peripheral vision in scene gist recognition. The results indicate that scene gist recognition can be accomplished with low-resolution peripheral vision as patients with central vision loss were able to recognize scenes with high accuracy in two types of categorization: natural versus urban scenes and indoor versus

TABLE 4. Difference in Performance between Categories in AMD and Control Groups

	Natural/Urban	Indoor/Outdoor	<i>P</i>
AMD			
Hit, %	84.4	79.2	<0.003
Response times, ms	565	628	<0.01
False alarms, %	6.4	11.6	<0.01
d' sensitivity	3.6	2.33	<0.01
Control			
Hit, %	96	95.4	NS
Response times, ms	548	579	NS
False alarms, %	2	5	<0.01
d' sensitivity	5.15	4.79	NS

NS, not significant.

outdoor scenes. The results therefore confirm Larson and Loschky's data with artificial scotomas in normally sighted people²⁰ and extend them to real scotomas varying from 5° to 30° eccentricity in our patients. This means that scene gist is available at low spatial resolution (peripheral vision) and even when local information, object identification, might help to distinguish between the two categories (e.g., a bed is more likely to be found indoors and a bike is more likely to be found outdoors).

An important debate in the literature^{17-19,22} is whether object recognition plays an important role in scene recognition, because identification of one or more prominent objects may be sufficient to activate a schema (a mental representation of a scene), and this facilitates recognition.²⁷ This "object-centered approach" implies normal central vision, given the importance of central vision for face and object recognition.¹⁴ Conversely, computer vision work^{28,29} and behavioral data^{21,22} have shown that real-world scenes can be identified at both superordinate (e.g., naturalness) and basic levels (e.g., forest) from low-level features (orientation and color) or more complex spatial properties such as texture, mean depth, and perspective, without the need for first identifying objects. Within this "scene-centered approach," the initial visual representation constructed by the visual system is at the level of the whole scene and not at the level of segmented objects.²⁸ Our results are more consistent with the notion that the initial scene representation is based on global properties and not on the objects it contains^{17,18} because central vision is reduced in AMD and object recognition is impaired.¹³

Although performance for scene categorization is high in patients with AMD (around 80% hits and d' above 2), performance was lower than in controls for both categories. The high accuracy observed in AMD patients can be explained by the fact that the task was simple and could be accomplished at a coarse spatial resolution based on low spatial frequencies. As expected, higher accuracy was observed in controls as they have use of their central vision, allowing object processing. Information presented at central vision is normally privileged and more efficient, producing greater gist recognition than peripheral vision on a per-pixel basis.²⁰

The results also show that, for patients with AMD, performance is better in naturalness (natural versus urban) than in indoor/outdoor categorization. This difference was not found in controls. Greene and Oliva¹⁸ suggested the possibility that the brain is able to rapidly calculate robust statistical summaries of features such as the average orientation of a pattern in an automatic fashion and outside the focus of attention. This might explain the advantage observed, particularly in patients with AMD, for naturalness compared with indoor/outdoor scenes, and also that, within naturalness, urban scenes were categorized faster and more accurately than natural scenes. Indeed, urban scenes (cities with high buildings in the set of images; see Fig. 1) were more homogeneous than natural scenes, including rivers, mountains, deserts, forests, and a beach. An advantage for naturalness has been reported in other studies. Naturalness classification had the fastest categorization threshold in Greene and Oliva's study¹⁷ and the fastest response times in the Joubert et al.²² study. An explanation for this difference is that a low resolution is sufficient to discriminate between natural and urban scenes, but a higher resolution is needed for basic-level scene categorization such as discrimination between sea, mountain, forests, and indoor and outdoor scenes.¹⁹

The fact that patients with AMD exhibit a better performance in naturalness than in indoor/outdoor categorization in the present study is consistent with reports of the impact of AMD on health-related quality of life⁴ as these questionnaires on daily activities are based on the indoor/outdoor environments

(e.g., going out to movies, going down stairs at night, reading street signs in the distance).

No correlation was found between performance and clinical variables such as the size of the lesion, visual acuity, and the type of AMD. Performance is found to be related to the size of absolute scotoma when high spatial frequencies are needed, for instance, in reading speed and in reading acuity.³⁰ The present results show that, in scene gist recognition, performance is unrelated to the size of the scotoma. This finding is consistent with Cahill and colleagues' study,⁵ who reported no correlation between the lesion size and peripheral vision or near and distance activity subscales of their questionnaire. Similarly, in our study, no relationship was found between visual acuity and performance of scene gist recognition, even if performance was lower in the AMD group than in controls.

Studies on scene recognition with normally sighted people have shown that observers are still able to recognize scenes under degraded viewing conditions such as low spatial resolution. For instance, with images filtered in spatial frequencies Oliva and Schyns³¹ showed that performance was above chance (60% correct) with coarse spatial scale information (4–6 cycles/image) in an indoor/outdoor scene categorization task. Macé et al.^{32,33} showed that normally sighted observers were able to detect the presence of an animal in a scene above chance at very low levels of contrast (6%). These results indicate that, as long as diagnostic information for task demand is available, a reliable perceptual gist may be structured quickly, based on a coarse description, at a resolution at which object information is so degraded that object identity cannot be recovered. Under impoverished viewing conditions, with a very low visual acuity, and central vision loss, people with AMD were able to extract diagnostic information and perform above 75% correctly.

It is important to acknowledge two limitations of the present work. First, the sample was small because it was difficult to find older AMD patients without cognitive impairment in a hospital. Second, conventional perimetry used in this study does not allow exact measurements of the size of the absolute scotoma.

In conclusion, we found that patients with AMD, with central vision loss, exhibit high accuracy for scene categorization, even if the performance is lower than that of age-matched controls. Accuracy is not correlated with visual acuity, lesion size, and scotoma size. Peripheral vision is sufficient for scene gist recognition. The role of peripheral vision in scene gist recognition is to be determined in further studies, including patients with peripheral vision loss (e.g., pigmentary retinopathy, glaucoma). Performance is lower in indoor/outdoor scene categorization, which is consistent with a reduced score of peripheral vision in previous studies on vision-related quality of life. Determining other properties of natural scenes such as the level of clutter and its impact on scene recognition in a future work might improve patients' performance and may assist them in orientation in their spatial environment.

Acknowledgments

The authors thank Aude Oliva for providing her photographs of scenes and to Lucie Descamps for testing participants.

References

1. Klaver CC, Wolfs RC, Vingerling JR, et al. Age-specific prevalence and causes of blindness and visual impairment in an older population: the Rotterdam Study. *Arch Ophthalmol*. 1998;116(5):653–658.
2. Cheung SH, Legge GE. Functional and cortical adaptations to central vision loss. *Vis Neurosci*. 2005(2);22:187–201.

3. Grill-Spector K, Malach R. The human visual cortex. *Annu Rev Neurosci.* 2004;27:649–677.
4. Mangione CM, Lee PP, Gutierrez PR, et al. Development of the 25-item National Eye Institute Visual Function Questionnaire. *Arch Ophthalmol.* 2001(7);119:1050–1058.
5. Cahill MT, Banks AD, Stinnett SS, Toth CA. Vision-related quality of life in patients with bilateral severe age-related macular degeneration. *Ophthalmology.* 2005(1);112:152–158.
6. Brody BL, Gamst AC, Williams RA, et al. Depression, visual acuity, comorbidity, and disability associated with age-related macular degeneration. *Ophthalmology.* 2001(10);108:1893–1900; discussion 900–901.
7. Legge GE, Rubin GS, Pelli DG, Schleske MM. Psychophysics of reading, II: low vision. *Vision Res.* 1985(2);25:253–265.
8. Legge GE, Rubin GS, Luebker A. Psychophysics of reading, V: the role of contrast in normal vision. *Vision Res.* 1987(7);27:1165–1177.
9. Legge GE, Ross JA, Luebker A, LaMay JM. Psychophysics of reading, VIII: the Minnesota Low-Vision Reading Test. *Optom Vis Sci.* 1989(12);66:843–853.
10. Tejeria L, Harper RA, Artes PH, Dickinson CM. Face recognition in age related macular degeneration: perceived disability, measured disability, and performance with a bioptic device. *Br J Ophthalmol.* 2002(9);86:1019–1026.
11. Peli E, Goldstein RB, Young GM, et al. Image enhancement for the visually impaired: simulations and experimental results. *Invest Ophthalmol Vis Sci.* 1991(8);32:2337–2350.
12. Boucart M, Dinon JF, Despretz P, et al. Recognition of facial emotion in low vision: a flexible usage of facial features. *Vis Neurosci.* 2008(4);25:603–609.
13. Owsley C, Sloane ME. Contrast sensitivity, acuity, and the perception of ‘real-world’ targets. *Br J Ophthalmol.* 1987(10);71:791–796.
14. Levy I, Hasson U, Avidan G, et al. Center-periphery organization of human object areas. *Nat Neurosci.* 2001(5);4:533–539.
15. Balas B, Nakano L, Rosenholtz R. A summary-statistic representation in peripheral vision explains visual crowding. *J Vis.* 2009(12);9:13.1–13.8.
16. Boucart M, Naili F, Despretz P, et al. Implicit and explicit object recognition at very large visual eccentricities: no improvement after loss of central vision. *Vis Cogn.* 2010(6);18:839–858.
17. Greene MR, Oliva A. The briefest of glances: the time course of natural scene understanding. *Psychol Sci.* 2009(4);20:464–472.
18. Greene MR, Oliva A. Recognition of natural scenes from global properties: seeing the forest without representing the trees. *Cogn Psychol.* 2009(2);58:137–176.
19. Oliva A. Gist of the scene. In: Itti L, Rees G, Tsotsos JK, eds. *Encyclopedia of Neurobiology of Attention.* San Diego, CA: Elsevier; 2005:251–256.
20. Larson AM, Loschky LC. The contributions of central versus peripheral vision to scene gist recognition. *J Vis.* 2009(10);9:6.1–6.16.
21. Rousselet GA, Joubert OR, Fabre-Thorpe M. How long to get to the gist of natural scenes? *Vis Cogn.* 2005(6);12:852–877.
22. Joubert OR, Rousselet GA, Fize D, Fabre-Thorpe M. Processing scene context: fast categorization and object interference. *Vis Res.* 2007(26);47:3286–3297.
23. Holz FG, Bindewald-Wittich A, Fleckenstein M, et al. Progression of geographic atrophy and impact of fundus autofluorescence patterns in age-related macular degeneration. *Am J Ophthalmol.* 2007(3);143:463–472.
24. Schmitz-Valckenberg S, Bultmann S, Dreyhaupt J, et al. Fundus autofluorescence and fundus perimetry in the junctional zone of geographic atrophy in patients with age-related macular degeneration. *Invest Ophthalmol Vis Sci.* 2004(12);45:4470–4476.
25. Tanner WP Jr, Swets JA. A decision-making theory of visual detection. *Psychol Rev.* 1954(6);61:401–409.
26. Markowitz SN, Muller C. Macular perimetry in low vision. *Can J Ophthalmol.* 2004(1);39:56–60.
27. Henderson JM, Hollingworth A. High-level scene perception. *Annu Rev Psychol.* 1999;50:243–271.
28. Oliva A, Torralba A. Modeling the shape of the scene: a holistic representation of the spatial envelope. *Int J Comput Vis.* 2001;42:145–175.
29. Torralba A, Oliva A. Statistics of natural image categories. *Netw Comput Neural Syst.* 2003(3);14:391–412.
30. Ergun E, Maar N, Radner W, et al. Scotoma size and reading speed in patients with subfoveal occult choroidal neovascularization in age-related macular degeneration. *Ophthalmology.* 2003(1);110:65–69.
31. Oliva A, Schyns P. Diagnostic colors mediate scene recognition. *Cogn Psychol.* 2000;41:176–210.
32. Mace MJ, Thorpe SJ, Fabre-Thorpe M. Rapid categorization of achromatic natural scenes: how robust at very low contrasts? *Eur J Neurosci.* 2005(7);21:2007–2018.
33. Mace MJ, Joubert OR, Nespoulous JL, Fabre-Thorpe M. The time-course of visual categorizations: you spot the animal faster than the bird. *PLoS ONE.* 2009(6);4:e5927.