

# Optokinetic Nystagmus Elicited by Filling-in in Adults with Central Scotoma

Christophe Valmaggia<sup>1</sup> and Irene Gottlob<sup>2</sup>

**PURPOSE.** Filling-in is the perceptual completion of physiological, pathologic, or artificial scotomas. Three patients are described, in whom optokinetic nystagmus (OKN) was present during filling-in.

**METHODS.** Three patients with age-related macular degeneration with large central scotomas were included in the study. OKN was elicited with black and white stripes moving nasally to temporally or temporally to nasally at four velocities. OKN gain was measured using infrared oculography.

**RESULTS.** While looking at the OKN stimuli, the patients either did not see the stimulus (without perceiving a positive scotoma) or filled in the scotoma and perceived the stripes. Simultaneously with filling in the scotoma, OKN eye movements were elicited in all three patients. The filling-in phenomenon was present for all stimulus directions and velocities, appeared within seconds, and was followed immediately by eye movements corresponding to OKN. OKN gains during filling-in were similar to those of age-matched control subjects without scotomas. No asymmetry was noted between temporal to nasal or nasal to temporal stimulation.

**CONCLUSIONS.** Motion-sensitive areas of the visual cortex may be activated and trigger the generation of OKN, supporting an active process. Alternatively, OKN is suppressed when subjects are not filling-in, while the subjects are fixating the central scotoma or edges of the scotoma. That the subjects did not perceive positive scotomas suggests that an active process is more likely. (*Invest Ophthalmol Vis Sci.* 2002;43:1804-1808)

Normally, when we look at a scene with one eye, we do not see a scotoma created by the blind spot or retinal vessels. This perceptual completion has been termed filling-in. It causes visual stimuli to be perceived as arising from an area of the visual field where there is no actual visual input.<sup>1</sup> Filling-in can occur, not only in physiological scotomas, but also in acquired lesions of the visual pathway.<sup>2</sup> For example, its existence is well described in glaucoma-related scotomas and leads to an underestimation of visual field defect.<sup>3</sup> Filling-in can also be elicited with artificial scotomas, corresponding to a hole in a textured field, which is steadily viewed in peripheral vision.<sup>1,4,5</sup>

The nature of the neuronal representation that corresponds to the filling-in process is poorly understood. It has been suggested that filling-in is not accomplished by ignoring the absence of information of the scotoma but by an active visual

process. This is supported by the possibility of filling in to occur separately for color and texture, suggesting separate mechanisms.<sup>5</sup> Even after an artificial scotoma has completely faded, it can contribute to motion perception.<sup>5</sup> Further evidence that filling-in is an active process comes from animal research in which neuronal activity in receptive fields corresponding to artificial scotomas has been shown in V1,<sup>6</sup> V2, and V3.<sup>7</sup> Filling-in due to an active process implies that receptive fields in the cortex can reorganize through cortical plasticity.

Optokinetic nystagmus (OKN) is a rhythmic involuntary eye movement elicited by a large moving pattern. It consists of slow eye movements in the same direction as the movement of the target and fast eye movements in the opposite direction. The quality of OKN can be measured with the OKN gain, corresponding to the ratio of slow-phase eye velocity and stimulus velocity. In patients with central scotomas in age-related macular degeneration (AMD) no significant decrease of OKN gain has been found.<sup>8,9</sup> It is not clear whether the intact peripheral retina alone is capable of eliciting OKN or whether cortical filling-in of the scotoma in AMD compensates for the absence of the stimulus. In this study, we present three patients with AMD who alternated perceiving the scotoma and seeing the OKN stimulus without scotoma by filling-in. Only during filling in was the OKN elicited. To our knowledge, this has not been described in the literature.

## METHODS

### Generating OKN and Recording Eye Movements

OKN stimulation and eye movement recordings and analysis were performed with vision monitor equipment (Metrovision, Perenchies, France). Visual stimuli were generated on a monitor, measuring 51 cm on the diagonal, that was placed 40 cm away from the eyes, with a frame rate of 120 Hz. The screen covered a visual field of 54° horizontally and 41° vertically. OKN was elicited with alternating white vertical stripes of a luminance of 70 cd/m<sup>2</sup> and black vertical stripes of a luminance of less than 1 cd/m<sup>2</sup>. Each stripe covered 2° of visual angle (equivalent to visual acuity of 20/2400). Stripes moved at a constant velocity of 15, 30, 45, or 60 deg/sec, either nasally to temporally or temporally to nasally for 40 seconds in random order. Subjects were investigated monocularly at all four stimulus velocities and both directions with a time interval of 2 minutes between the trials. Subjects were instructed to look at the center of the visual field and not to follow the stripes.

Eye movements were recorded by measuring the position of the corneal reflex with respect to the center of the pupil. A near infrared illumination of the eye (880 nm) was used to produce the corneal reflex and the pupil image. The system operated with a sampling rate of 60 Hz and achieved a resolution of 10 min arc. The examiner observed the position of the eye, monitored with a video camera, and eye movement recordings on computer monitors during the test. Analysis of eye movements included the detection of the slow and fast phases of OKN and the determination of the mean velocity for the slow phases. The OKN gain was defined as the ratio of mean slow-phase velocity to stimulus velocity. Duration of OKN was measured from the beginning to the end of each eye movement segment of periodic slow and fast phases.

---

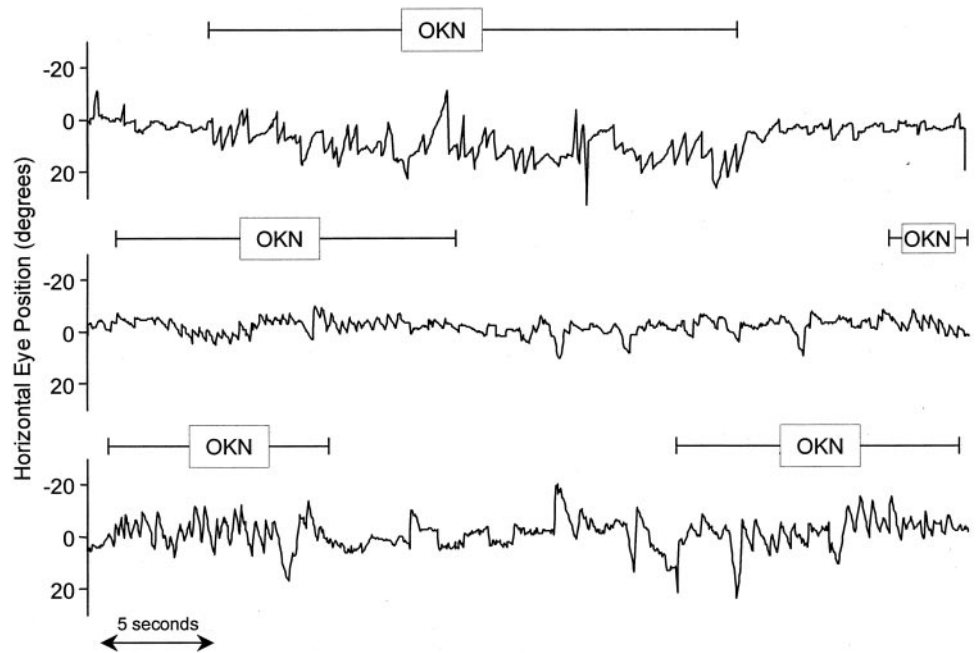
From the <sup>1</sup>Department of Ophthalmology, Kantonsspital St. Gallen, Abtwil, Switzerland; and the <sup>2</sup>Department of Ophthalmology, University of Leicester, Warwick Medical School, Leicester, United Kingdom.

Submitted for publication July 12, 2001; revised December 21, 2001; accepted January 17, 2002.

Commercial relationships policy: N.

The publication costs of this article were defrayed in part by page charge payment. This article must therefore be marked "advertisement" in accordance with 18 U.S.C. §1734 solely to indicate this fact.

Corresponding author: Christophe Valmaggia, Sonnenbergstrasse 36, CH-9030 Abtwil, Switzerland; valmaggia@freesurf.ch.



**FIGURE 1.** Photograph-oculographic recordings of the left eyes of the three patients during stimulation of OKN. For patient 1 (*top tracing*) stripes were moving temporally to nasally, at a velocity of 30 deg/sec, and for patients 2 (*middle tracing*) and 3 (*bottom tracing*) stripes were moving nasally to temporally at a velocity of 45 and 60 deg/sec, respectively. Filling-in of the scotoma with corresponding generation of OKN is indicated by *horizontal bars*.

## Patients

The study was approved by the local ethics committee. Informed written consent was obtained from each patient after explanation of the nature of the investigation. The study was performed in accordance with tenets of the Declaration of Helsinki.

Three patients were selected from an ongoing study of 60 patients with AMD, which was undertaken to investigate the effect of the size of scotoma on OKN gain.<sup>9</sup> These patients were selected for the present study, because they were the only patients spontaneously able to perceive the scotoma at some times and to see the OKN stimulus on the whole monitor at other moments. All other patients included in the previous study<sup>9</sup> continuously perceived the stimulus.

Each patient had a complete ophthalmic examination, including simultaneous fluorescein and indocyanine green angiography. The size of the absolute scotoma was measured with the mark Ie4 (0.25 mm<sup>2</sup> and 318 cd/m<sup>2</sup>) of the Goldmann perimeter, using a standard background luminance (10 cd/m<sup>2</sup>). Patients had no history of strabismus, amblyopia, glaucoma, or diabetic retinopathy.

**Patient 1.** This 80-year-old woman had an occult subfoveal neovascularization in the left eye causing a central scotoma of 15°. The distance visual acuity was OS 20/200. The patient had reported central scotoma and metamorphopsia for 6 months. Her right eye showed discoid maculopathy. Distance visual acuity was OD 20/2000. The patient was treated with aspirin because of episodes of transient ischemia.

**Patient 2.** This 82-year-old woman had an occult subfoveal neovascularization in the left eye with a central scotoma of 18°. The distance visual acuity was OS 20/125. The patient had reported central scotoma for 2 months. Her right eye had dry AMD. Distance visual acuity was OD 20/30. The patient was treated with quinapril and hydrochlorothiazide for hypertension.

**Patient 3.** This was a 63-year-old woman with an occult subfoveal neovascularization in the left eye with a central scotoma of 16°. Distance visual acuity was OS 20/250. The patient had reported a central scotoma and metamorphopsia for 2 months. Her right eye had dry AMD. Distance visual acuity was OD 20/60. The patient was otherwise healthy and was taking no medication.

When asked how they perceived the scotoma, the patients found it difficult to describe it. They described that they had a missing part that resembled a hole in the center of the visual field. They did not perceive a positive scotoma, such as a gray area in the center of the field. They

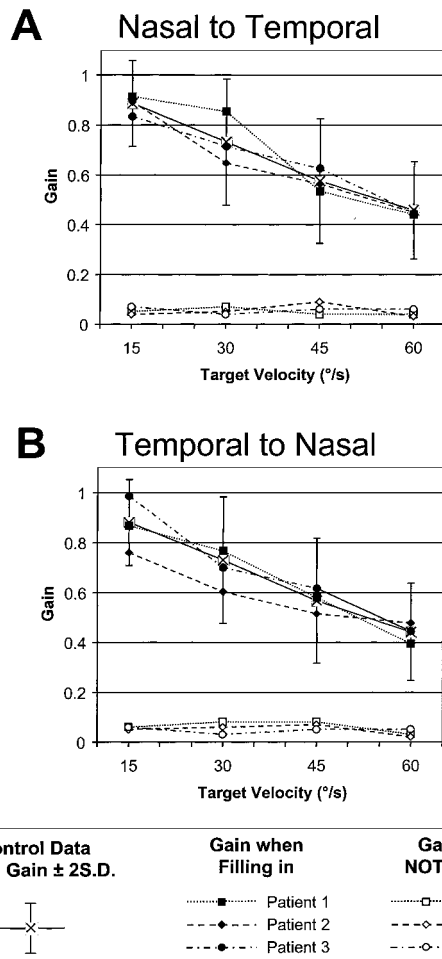
perceived patterns from the periphery. For example, when looking at the visual field chart, they saw the letters in the periphery but did not recognize the letter at which they attempted to look. Colors and other patterns from the periphery of the visual field invaded the scotoma and they could not delineate the edges of the scotoma. When looking at different backgrounds, such as the examiner's face, they could not clearly delineate the size of the scotoma and described frequent changes. When they looked at a uniform background they did not perceive the scotoma.

All three patients experienced filling-in while they were observing the OKN stimulus with their left eyes, which had extensive scotomas and very low visual acuities. Only OKN recordings obtained from those eyes were included in this study. They were compared with OKN measurements from a control group of 20 age-matched patients with macular degeneration but without scotoma (mean age, 71.4 years; mean distance visual acuity, 20/30). These control data were established in a previous study<sup>9</sup> under exactly the same experimental conditions.

## RESULTS

The filling-in phenomenon was present in the three patients for all stimulus directions and velocities. The three patients described spontaneously how the central scotoma was filled quickly by the pattern of moving black and white stripes arising from the neighboring areas of the visual field, and they simultaneously started to have OKN. Patients indicated verbally the beginning and the end of the filling-in. During filling-in OKN was generated, and while the scotoma was perceived, no OKN was elicited. Figure 1 shows examples of eye movement recordings in each patient during phases of no perception of the stimulus with minimal OKN, alternating with filling-in and generation of OKN.

OKN occurred immediately after the patient indicated filling-in and was frequently observed promptly (1–2 seconds) after presentation of the stimuli (Figure 1, patients 2 and 3). No periodicity of the occurrence of the OKN was observed. The mean time of filling-in for all stimuli was 14.6 seconds (range, 9–20 seconds) for patient 1, 11.25 seconds (range, 6–19 seconds) for patient 2, and 14.75 seconds (range, 9–20 seconds) for patient 3. At the same time as patients experienced fill-



**FIGURE 2.** Mean  $\pm$  SD OKN gain during stimulation nasally to temporally (A) and temporally to nasally (B) with stripes moving at 15, 30, 45, and 60 deg/sec, measured in 20 eyes of age-matched patients without scotoma and OKN gains of the three patients when filling in and when not filling in.

ing-in, the generation of OKN was present at all stimulus directions and velocities.

During filling-in of the scotoma, the gains of the generated OKN were similar to the OKN gains measured of control patients of the same age without scotoma. OKN gains during filling-in were within two SDs of the mean OKN gains measured in the control group (Fig. 2). No asymmetries of the OKN between temporal to nasal and nasal to temporal stimulation were observed in the three patients in this study. When the patients did not fill in there was only a minimal OKN gain, which did not change with stimulus velocity (Fig. 2).

At a second examination 1 year later, the three patients perceived continuously the OKN stimulus, and eye movement recordings showed OKN during the entire test.

## DISCUSSION

We demonstrate in this study that ocular movements such as OKN can be triggered by filling-in. Filling-in of the scotoma appeared within seconds and was followed immediately by eye movements corresponding to OKN. The gain of the OKN during filling-in periods was comparable to that of control subjects without scotoma. No horizontal OKN asymmetries were observed during filling-in. When patients did not fill in, the OKN gain was only minimal.

Whether filling-in of the blind spot or artificial scotomas in normal subjects is accomplished by ignoring the absence of information<sup>10,11</sup> or by an active process is a subject of debate. Using artificial scotomas in normal human subjects, Ramachandran and Gregory<sup>5</sup> found several phenomena that strongly support an active process: (1) The filling-in process appeared gradually, with the borders of the artificial scotoma fading slowly from the outside to the inside; (2) filling-in for color and texture did not occur simultaneously; (3) if a square used as an artificial scotoma was filled in, then suddenly replaced by a smaller one in the same area, the subject became aware first of a scotoma with the size of the small square, which again took several seconds to fade; (4) if the faded square was shifted the subject experienced sensation of motion; (5) if a small spot was introduced in an already faded area, the subjects perceive it; (6) if the background was changed, the faded area appeared before being filled in again. Pettet and Gilbert<sup>6</sup> recorded from single cells in cat area 17, corresponding to a masked area in the visual field, while stimulating the surrounding region. Over 10 minutes, a fivefold average expansion in the receptive field occurred. When the center of the receptive field of the same cell was directly stimulated, the expansion was reversed, and the receptive field size collapsed and returned to its original size. De Weerd et al.<sup>7</sup> showed in similar experiments in monkeys that the time course of activation of cells in the extrastriate cortex (V2 and V3) parallels the time course of filling-in in humans and occurs over several seconds rather than minutes. They also showed that the climbing activity of cells is more pronounced in the extrastriate cortex than in V1. A possible explanation is that filling in reflects the activity of higher extrastriate neurons and that feedback pathways are used to create a representation of the surround in the portion of area 17 that corresponds to the scotoma.<sup>5,7</sup>

Results from animal studies suggest that two pathways are responsible for generation of OKN.<sup>12</sup> The corticopontocerebellar neuronal pathway includes area V5 of the cortex and the dorsolateral pontine nucleus of the brain stem, which projects to the oculomotor centers through the cerebellum. This has a rapid build-up usually within less than 1 second and usually dominates normal OKN. The second pathway consists primarily of subcortical structures, the nucleus of the optic tract being an essential afferent link in the production of OKN. The subcortical OKN has a slow build-up and slow decay (optokinetic after-nystagmus). Functional magnetic imaging studies in humans support the OKN pathway found in animal research. They localized brain activity during OKN to the primary visual cortex, the motion-sensitive areas in the extrastriate cortex (the middle temporal area or V5 and the medial superior temporal areas) and in areas known to control eye movements (the frontal, parietal, and supplementary eye fields). In addition, activity was found in the anterior and posterior parts of the insula, subcortical areas, and the cerebellum.<sup>13,14</sup>

In our study the OKN was elicited within 1 or 2 seconds after the beginning of the stimulus or promptly after the perception of the filling-in of the visual field. This argues for involvement of cortical areas. Moving black-and-white stripes, as in our experiments, trigger strong neuronal activity in the motion-sensitive extrastriate visual cortex.<sup>15</sup> Previous experiments<sup>7</sup> suggest that the filling-in primarily occurs in extrastriate visual cortex. Therefore, it is likely that the filling-in in our patients activated primarily extrastriate motion-sensitive areas, which in return gave feedback to the primary visual cortex on the one hand and to motor control areas on the other hand.

In infants and patients deprived of normal binocular vision, there is a monocular OKN asymmetry, with the beat frequency, speed, and amplitude of the slow phase being higher when the stimulus moves temporally to nasally.<sup>12,15-20</sup> It has been pos-



tulated that this asymmetric horizontal OKN is mediated by the subcortical OKN pathway and that a fully developed foveal area is essential for development of symmetrical OKN.<sup>16-19</sup> The three patients in this study did not show horizontal OKN asymmetries during filling-in. In a previous study including a large number of patients with AMD,<sup>9</sup> we did not find horizontal OKN asymmetries and concluded that scotomas acquired later in life do not modify the previously developed symmetry. An explanation for symmetrical OKN despite large central scotomas may be that in AMD cortical centers become primary sites of generation of OKN through filling-in, and the role of the central retina is less important.

Examined with the Amsler grid, smaller scotomas up to 6° in diameter show a higher percentage of filling-in than larger ones.<sup>3</sup> These observations are in agreement with the results of experiments in cats showing that, in the cortex, no unresponsive area could be found with retinal lesions 5° to 10° in diameter, whereas unresponsive areas are found with larger lesions.<sup>6</sup> Our findings showed that in our three patients the filling-in phenomenon was present in scotomas as large as 18°. The extent of filling in is dependent on the background stimulus,<sup>5</sup> and therefore the black-and-white moving bars may be a stronger stimulation for filling-in than a stationary pattern such as an Amsler grid.

The impact of loss of the central visual field on OKN gain has been debated. Hood<sup>21</sup> described one patient with central scotoma who exhibited accelerated OKN. In other studies in patients with AMD, no significant differences or only slightly reduced gains have been found, compared with control subjects without scotoma.<sup>8,9</sup> This has been explained by assuming that peripheral retinal areas are sufficient to stimulate OKN. However, even small artificial central scotomas may lead to a large reduction in OKN gain. With central artificial scotomas, filling-in is usually not possible, because the scotoma itself is seen and OKN is suppressed through fixation.<sup>15,22-29</sup> In experiments with retinal stabilized scotomas, the scotoma itself can be seen to move and can become a stimulus for further movement or can be used to stare at while the moving stripes are neglected.<sup>23</sup> In studies of artificial scotomas the edge-effect of the mask used to create central field defect or the presence of lines in the central visual field are likely to contribute to suppression of the OKN. Schor and Narayan<sup>27</sup> found that reduction of the gain of OKN is due mainly, if not entirely, to the presence of sharp lateral boundaries fixed near the central visual field, rather than to the narrowing of the display. Murasugi et al.<sup>28</sup> found reduction in OKN gain when edges were within 10° to 15° of the fovea. When stationary edges were not parallel to the direction of the motion of the stimulus, reduction in OKN was eliminated. Similarly, inhibition of the OKN was reduced when stationary boundaries were eliminated by blurring edges, when central and peripheral regions were equated for contrast and the stimulus contained no high spatial frequencies, which are more visible in the central retina.<sup>29</sup> Our patients did not describe a positive scotoma with distinct edges. However, they had difficulties describing the scotomas. Therefore, suppression of OKN during periods of non-filling-in by fixating the scotoma or edges of the scotoma cannot be excluded. The range of scotoma size in our patients of between 15° and 18° correspond to the location of edges suppressing OKN used by Murasugi et al.<sup>28</sup> In this case, the peripheral retina alone could elicit the OKN, whereas during periods of non-filling-in the OKN may have been suppressed.

In most experiments in patients with central scotomas,<sup>8,9</sup> including those in this study, patients were instructed to look at the center of the screen. Thus, these instructions would be likely to elicit "stare OKN," which has low gain and amplitude and frequent quick phases, as opposed to "look OKN," in which the subject follows single details of the stimulus with

high-gain, large-amplitude, and infrequent quick phases.<sup>12</sup> Despite instruction of the subjects, it is difficult to know which of the OKN types filling-in would elicit. Control subjects in this study had the same instructions as the three patients who experienced filling in. In our previous experiment<sup>9</sup> the same instruction to use stare OKN in subjects without scotomas and with scotomas under 20° did not show differences between the two groups. The different characteristics of look OKN are attributed to activation of smooth pursuit.<sup>12</sup> Therefore, patients with central scotomas may show different characteristics if they are specifically instructed to follow the stimuli.

OKN has been shown to be dependent on attention. Using artificial scotomas Cheng and Outerbridge<sup>22</sup> showed that OKN was absent until the subjects' attention was directed toward the peripheral portion of the stimulus. Inverted OKN was induced in investigations of patients with large central scotomas by actively directing attention to the central field defect itself.<sup>30,31</sup> In this central-peripheral interaction the investigators proposed an important role for spatially selective attention. The difference in our patients, however, was that they clearly indicated filling-in of the scotoma shortly before the OKN was elicited, whereas this was not described in the patients included in the studies mentioned. It is possible that attention was involved in our patients to elicit filling-in.

During filling-in, our subjects perceived the pattern in the central visual field. Therefore, cortical areas corresponding to the scotoma may have been stimulated through expansion of receptive fields and/or feedback pathways, rather than directly through afferent neuronal activity from the retina. The filling-in phenomenon occurring in patients with central scotomas but not in central artificial scotomas may therefore explain this discrepancy found in the literature.

One important implication of the filling-in mechanism is the potential of plasticity in the adult visual cortex after an acquired lesion.<sup>1,3</sup> This is supported by our result showing rapid changes between perception of the scotoma and filling-in linked to generation of OKN. Cortical plasticity in our three patients is also supported by the change of the pattern of filling in with time. Examined 1 year later, they had constant generation of OKN. Similarly, in our previous study,<sup>9</sup> all patients, independently of the size of their scotomas, constantly perceived the OKN stimulus and exhibited OKN. This may also be explained by long-term cortical adaptation.

In conclusion, we observed generation of eye movements linked to perceptual filling-in. The timing of perception of filling-in and generation of OKN is similar to activity of cells measured during filling-in in animal experiments. It is therefore possible that motion-sensitive areas in the extrastriate visual cortex primarily trigger the generation of OKN during filling-in, due to an active process. Alternatively, OKN was suppressed during the absence of filling-in, while the subjects fixated the central scotoma or edges of the scotoma, as in experiments with artificial scotomas. Because our subjects did not perceive a positive scotoma, we suggest that an active process is more likely.

## References

1. Safran A, Landis T. From cortical plasticity to unawareness of visual field defects. *J Neuroophthalmol.* 1999;19:84-88.
2. Gerrits H. The filling-in process in patients with retinal scotomata. *Vision Res.* 1969;9:439-442.
3. Safran A, Landis T. Plasticity in the adult visual cortex: implications for the diagnosis of visual field defects and visual rehabilitation. *Curr Opin Ophthalmol.* 1996;7:53-64.
4. Ramachandran V. Blindspots. *Sci Am.* 1992;266:85-91.
5. Ramachandran V, Gregory R. Perceptual filling-in of artificially induced scotomas in human vision. *Nature.* 1991;350:699-702.

6. Pettet M, Gilbert C. Dynamic changes in receptive-field size in cat primary visual cortex. *Proc Natl Acad Sci USA*. 1992;89:8366-8370.
7. De Weerd P, Gattass R, Desimone R, Ungerleider L. Responses of cells in monkey visual cortex during perceptual filling-in of an artificial scotoma. *Nature*. 1995;377:731-734.
8. Abadi R, Pantazidou M. Monocular optokinetic nystagmus in humans with age-related maculopathy. *Br J Ophthalmol*. 1997;81:123-129.
9. Valmaggia C, Charlier J, Gottlob I. Optokinetic nystagmus generation in central scotomas. *Br J Ophthalmol*. 2001;85:169-172.
10. Dennett D. *Consciousness Explained*. Boston: Little, Brown; 1991.
11. O'Reagan J. No evidence for neural filling-in-vision as an illusion-pinning down, enaction. *Behav Brain Sci*. 1998;21:767-768.
12. Garbutt S, Harris C. A review of optokinetic nystagmus (OKN) in infants and children. *Br Orthopt J*. 1999;56:1-10.
13. Dietrich M, Bucher S, Seelos K, Brandt T. Horizontal or vertical optokinetic stimulation activates visual motion-sensitive, ocular motor and vestibular cortex areas with right hemispheric dominance: an fMRI study. *Brain*. 1998;121:1479-1495.
14. Dietrich M, Bucher S, Seelos K, Brandt T. Cerebellar activation during optokinetic stimulation and saccades. *Neurology*. 2000;54:148-155.
15. Schor C, Levi D. Disturbance of small-field horizontal and vertical optokinetic nystagmus in amblyopia. *Invest Ophthalmol Vis Sci*. 1980;19:668-683.
16. Atkinson J, Braddick O. Development of optokinetic nystagmus in infants: an indicator of cortical binocularity? In: Fisher D, Monty R, Senders J, eds. *Eye Movements: Cognition And Visual Perception*. Hillsdale, NJ: Erlbaum; 1981:53-64.
17. Yee R, Baloh R, Honrubia V, et al. Pathophysiology of optokinetic nystagmus. In: Honrubia V, Brazier M, eds. *Nystagmus and Vertigo*. London: Academic Press, 1982:251-275.
18. Naegele J, Held R. The postnatal development of monocular optokinetic nystagmus in infants. *Vision Res*. 1982;22:341-346.
19. Lewis T, Maurer D, Smith R et al. The development of symmetrical optokinetic nystagmus during infancy. *Clin Vis Sci*. 1992;7:211-218.
20. Weinacht S, Kind C, Schulte Mönning J, Gottlob I. Visual development in preterm and full-term infants: a prospective masked study. *Invest Ophthalmol Vis Sci*. 1999;40:346-353.
21. Hood J. Observation upon the role of the peripheral retina in the execution of eye movements. *Otorhinolaryngology*. 1975;37:65-73.
22. Cheng M, Outerbridge J. Optokinetic nystagmus during selective retinal stimulation. *Exp Brain Res*. 1975;23:129-139.
23. Gresty M, Halmagyi M. Following eye movements in the absence of central vision. *Acta Otolaryngol*. 1979;87:477-483.
24. Dubois M, Collewijn H. Optokinetic reactions in man elicited by localised retinal motion stimuli. *Vision Res*. 1979;19:1105-1115.
25. Van Die G, Collewijn H. Optokinetic nystagmus in man: role of central and peripheral retina and occurrence of symmetries. *Hum Neurobiol*. 1982;1:111-119.
26. Van Die G, Collewijn H. Control of optokinetic nystagmus by the central and peripheral retina: effects of partial visual field masking, scotopic vision and central retinal scotomata. *Brain Res*. 1986;383:185-194.
27. Schor C, Narayan V. The influence of field size upon the spacial frequency response of optokinetic nystagmus. *Invest Ophthalmol Vis Sci*. 1981;21:985-994.
28. Murasugi C, Howard I, Ohmi M. Optokinetic nystagmus: the effect of stationary edges, alone and in combination with central occlusion. *Vision Res*. 1986;26:1155-1162.
29. Howard IP, Ohmi M. The efficiency of the central and peripheral retina in driving human optokinetic nystagmus. *Vision Res*. 1984;24:969-976.
30. Crevits L, van Vliet A. Optokinetic nystagmus in patients with defects of the central visual field. *Eur Neurol*. 1986;25:454-457.
31. Crevits L. Optokinetic nystagmus in patients with central visual field defects (Letter). *Br J Ophthalmol*. 2001;85:762.