



Iris changes and pupillometry in Nevus of Ota

Ruchita Sontakke & Paromita Dutta

To cite this article: Ruchita Sontakke & Paromita Dutta (17 Dec 2024): Iris changes and pupillometry in Nevus of Ota, Clinical and Experimental Optometry, DOI: [10.1080/08164622.2024.2441264](https://doi.org/10.1080/08164622.2024.2441264)

To link to this article: <https://doi.org/10.1080/08164622.2024.2441264>



Published online: 17 Dec 2024.



Submit your article to this journal [↗](#)

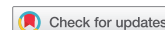

View related articles [↗](#)



View Crossmark data [↗](#)

CLINICAL PICTURE



Iris changes and pupillometry in Nevus of Ota

Ruchita Sontakke and Paromita Dutta

Department of Ophthalmology, Guru Nanak Eye Centre, Maulana Azad Medical College, New Delhi, India

ARTICLE HISTORY Received 22 August 2024; Revised 16 October 2024; Accepted 5 December 2024

KEYWORDS Iris; Nevus of Ota; pupillometry

Introduction

Oculodermal melanocytosis, also known as Nevus of Ota, is a benign melanosis that primarily involves the region supplied by the ophthalmic and maxillary branches of the trigeminal nerve.¹ It is a flat, melanotic lesion of skin and mucosae characterised by brown or blue-grey colouration, oval-shape, and poorly defined contours that can involve the episclera, sclera, and uvea of the eye.² This case report presents the finding of asymmetric pupillary light reflex in the case of Nevus of Ota.

Case description

A 27-year-old woman of Asian ethnicity was detected with lesions suggestive of the left-sided Nevus of Ota. She was evaluated for glaucoma and choroidal melanoma but was found to have none. Best corrected visual acuity was R&L: 6/6. Anterior segment examination revealed episcleral bluish pigmentation and iris heterochromia of the left eye.

Applanation tonometry recorded intraocular pressure of R: 18 mmHg and L: 20 mmHg. Gonioscopy showed open angles in both eyes with increased trabecular meshwork pigmentation in the left eye. Fundus examination showed mild retinal pigmentary mottling in the left eye when compared with the right eye.

Pupillary examination in daylight revealed mild anisocoria and heterochromia. The pupillary light reflex responses were

measured using a computerised automated pupillometry system (MonoPack One; Metrovision, France). Pupillary responses were recorded with white light stimulus in a completely dark environment (light intensity: 100 cd/m², on/off duration: 200/3300 ms). In scotopic light, the pupils showed anisocoria (Figure 1A) and a smaller pupil diameter of the affected eye, while this difference was not present under photopic stimulation (Figure 1B). Note the iris heterochromia of the left eye. The pupillary light reflex shows a reduced amplitude and duration of contraction, along with a slower velocity of contraction in the affected eye (Figure 2). The affected pupil also has a shorter latency but a longer duration of dilation.

These findings suggest that pupillary sphincter is more affected than the dilator muscle. Anterior segment optical coherence tomography of right eye showing normal iris architecture (Figure 3A) while left eye showed increased thickness of iris stroma compared with the right eye, with loss of normal iris architecture (Figure 3B). Iris sphincter thickness could not be determined because of diffuse hyperpigmentation, which obstructed the visibility of structures posterior to the anterior surface of the iris.

Discussion

Nevus of Ota affects the iris tissue which can lead to thickening of the iris stroma. This can range from the presence of

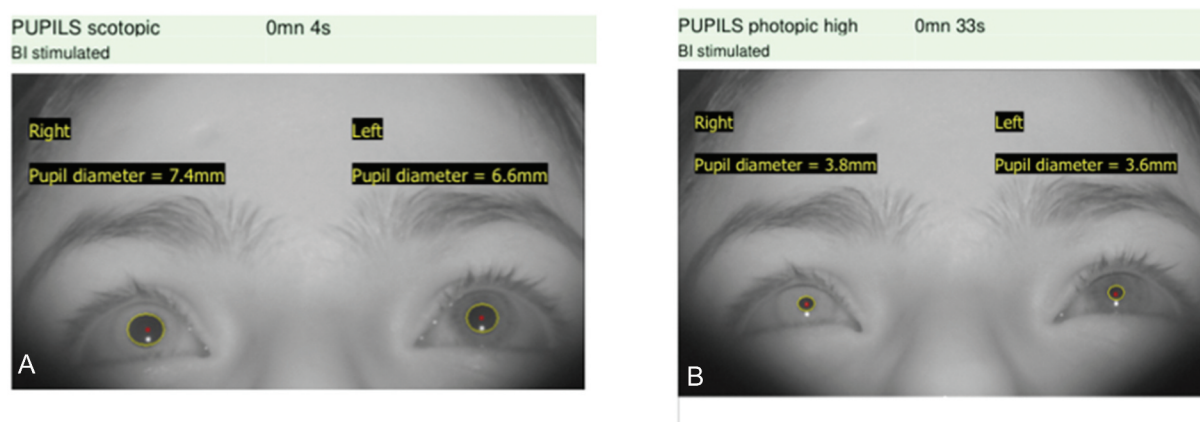


Figure 1. A: Scotopic pupillometry showing anisocoria and smaller pupillary diameter of left eye. B: Photopic pupillometry showing mild asymmetry in pupillary diameter suggesting anisocoria is greater in the dark.

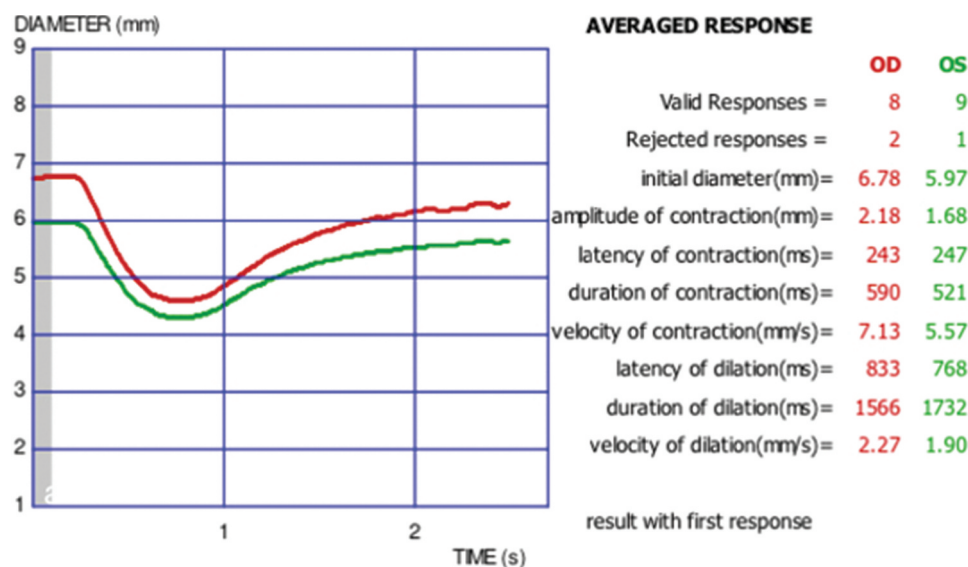


Figure 2. Pupillary light reflex showing lesser amplitude and velocity of contraction of left eye as compared to right eye. Note the greater duration of dilatation of left eye.

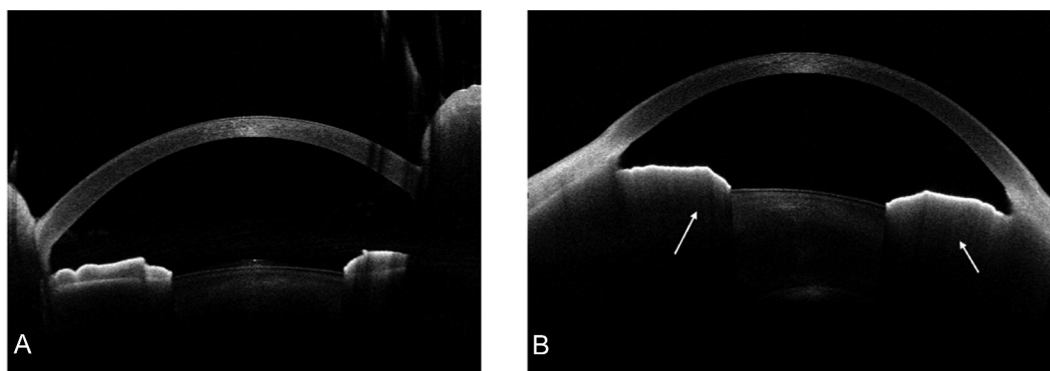


Figure 3. A: Anterior segment optical coherence tomography of the right eye showing normal iris architecture as compared with right eye. Note the back shadowing (arrows) due to increased thickness and pigmentation of the affected eye.

stellate granules only with no effect on the iris structure, to diffuse pigmentation which obscures the underlying iris architecture. The condition is characterised by melanocyte proliferation in the anterior border and iris stromal layers. Rennie et al. reported that the affected iris demonstrates the presence of numerous melanocytes in the anterior border and iris stromal layers.³ In the absence of conjunctival and episcleral pigmentation, these changes can represent the initial manifestations of nevus of ota. Increased thickness and reduction of flexibility of the iris stroma can lead to a loss of iris crypts.⁴

These mechanical changes in iris ultrastructure affect the pupil size and response to light. Open-angle glaucoma secondary to blockage of the angle by melanocytes is most commonly seen.⁵ Secondary angle closure is very rare. Since patients with this oculodermal melanocytosis may develop glaucoma, this presentation needs to be considered as a confounding factor when evaluating automated pupillometry in glaucoma. Anterior segment optical coherence tomography can be helpful for assessing structural changes of the iris and correlating this with the development of glaucoma.

Recent studies have reported the association between the loss of iris crypts and the development of glaucoma. These ultrastructural changes should be examined further for early

detection of glaucoma and other complications in these patients.

Disclosure statement

No potential conflict of interest was reported by the author(s).

ORCID

Ruchita Sontakke <http://orcid.org/0000-0002-8472-4465>

References

- Junejo MS, Khan MS, Mukhtar A et al. Ocular features in a case of Nevus of Ota. *J Coll Physicians Surg Pak* 2017; 27: S56–S57.
- Baykal C, Yilmaz Z, Sun GP et al. The spectrum of benign dermal dendritic melanocytic proliferations. *J Eur Acad Dermatol Venereol* 2019; 33: 1029–1041.
- Rennie IG, Bleehe SS. Melanosis oculi: an ultrastructural study of an affected iris. *Arch Ophthalmol* 1983; 101: 1912–1916.
- Vishnevskia-Dai V, Moroz I, Davidy T et al. Naevus of Ota: clinical characteristics and proposal for a new ocular classification and grading system. *Br J Ophthalmol* 2020; 105: 42–47.
- Teekhasaene C, Ritch R, Rutnin U et al. Glaucoma in oculodermal melanocytosis. *Ophthalmology* 1990; 97: 562–570.