

Acute Macular Neuroretinopathy (AMNR). Covid NeuroRétinite maculaire aiguë (Covid)

Jean-Michel Muratet, MD

[Contact](#)

Man, 36 years old

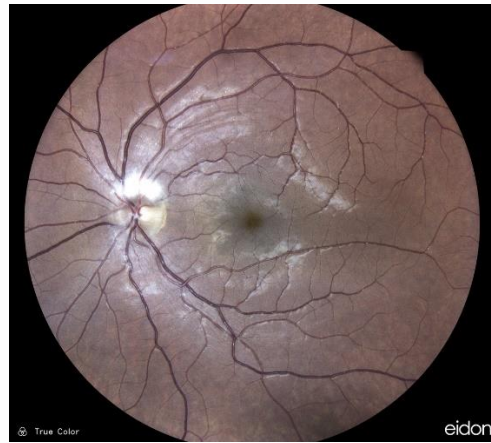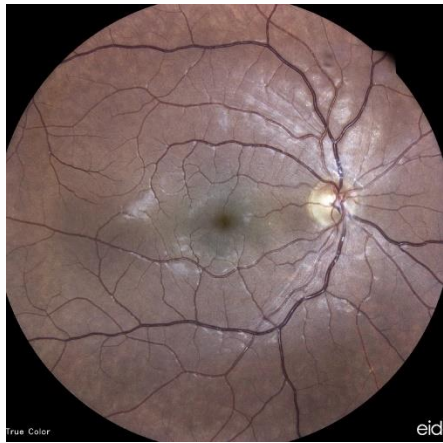Reddish-brown petalloid perifoveal lesions

Lésions pétaloïdes périfovéolaires

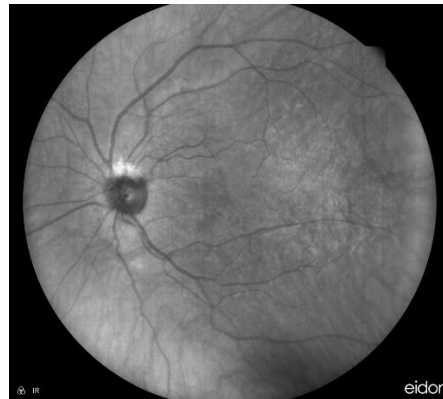
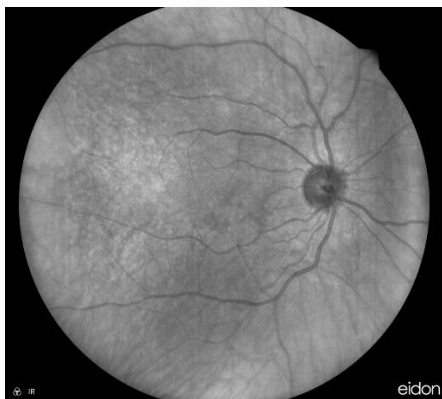
Paracentral scotomas

Effondrement de l'acuité visuelle de loin et de près, avec scotomes paracentraux très gênants

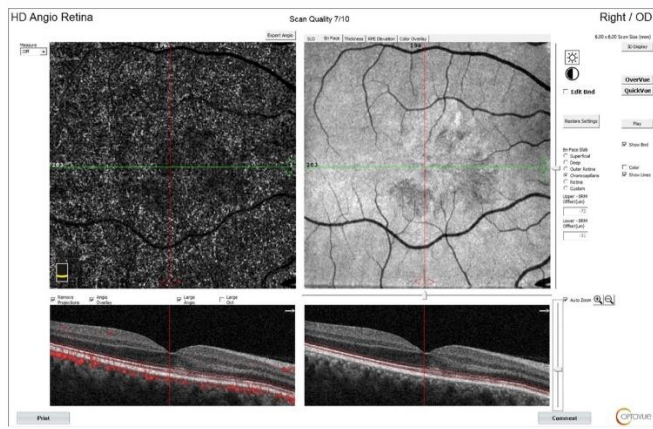
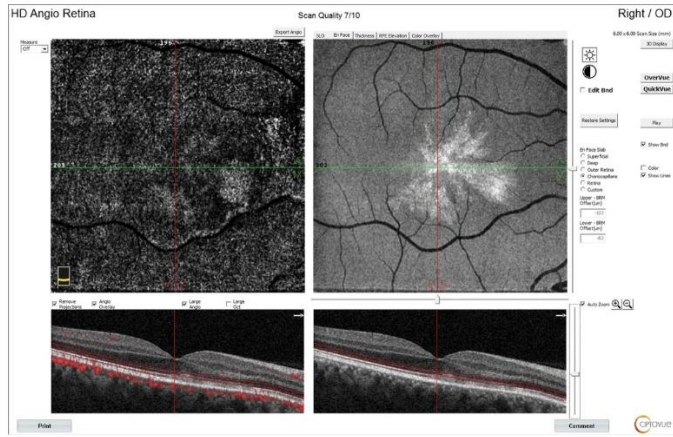
AMNR EIDON

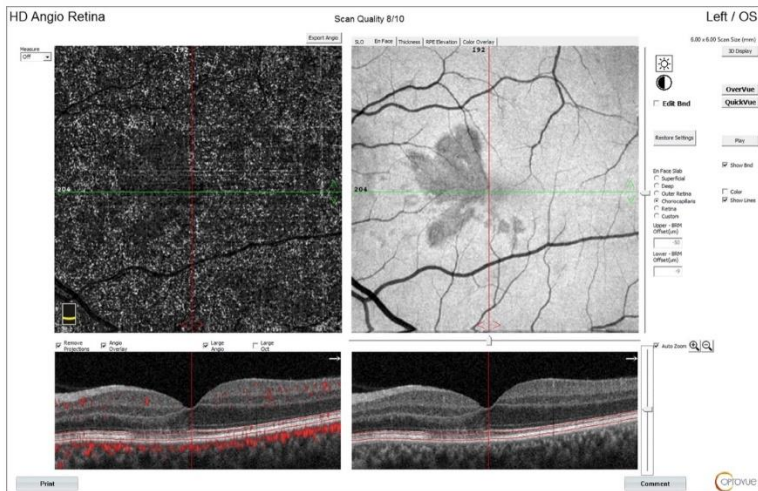
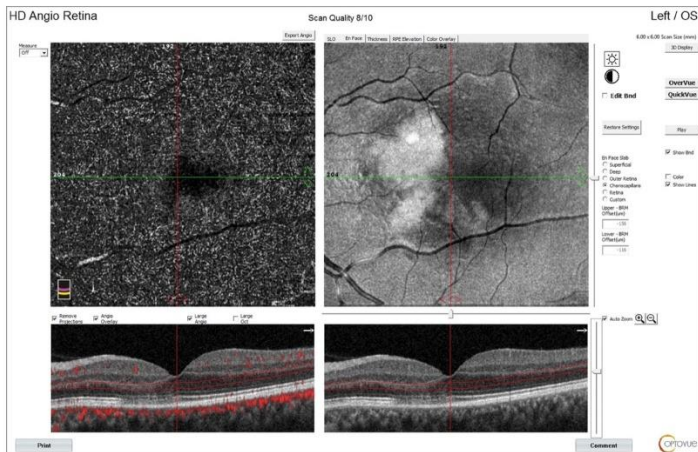


IR EIDON



OCT ANGIOGRAPHY OPTOVUE





VISUAL FIELD Metrovision

