

Original Article

Radiation-Induced Ocular Surface Disorders and Retinopathy: Ocular Structures and Radiation Dose-Volume Effect

Ozlem Ozkaya Akagunduz¹, Suzan Guven Yilmaz², Emin Tavlayan¹, Mine Esen Baris², Filiz Afrashi², Mustafa Esassolak¹

Departments of ¹Radiation Oncology and ²Ophthalmology, Ege University Faculty of Medicine, Izmir, Turkey

Purpose This study aimed to evaluate the radiation-induced adverse effects on ocular structures in head and neck cancer patients and investigate the radiation dose-volume effects on the cornea, lacrimal gland, retina, optic nerve and chiasm.

Materials and Methods A total of 38 eyes of 19 patients were included in this prospective, cohort study. All patients underwent complete ophthalmological examination in addition to contrast sensitivity, visual field and visual evoked potentials (VEP) tests. Ophthalmological examinations and psychophysical tests were performed in 6th, 12th, 18th, 24th months and in the last visit. The relationship between the ophthalmologic findings, and the radiation doses below and above the cut-off values was evaluated.

Results Contrast sensitivity decrease and visual field deterioration were observed in 42% of the patients in the last visit (median 26 months) whereas a prolonged latency and decreased amplitude of P100 wave in VEP was observed in 58% and 33% of the eyes, respectively at 24th month. Totally 16 patients (84.2%) developed dry eye disease and eight of them received radiotherapy below tolerance doses and had mild to moderate dry eye findings. Radiation-induced retinopathy was observed in three of the eyes in eight patients who received radiation above tolerance dose.

Conclusion Head and neck cancers treated with radiotherapy, resulted in various ophthalmic complications. All patients who are treating with radiotherapy should be evaluated by an ophthalmologist in terms of anterior and posterior segment damage, even if the radiation dose is below the tolerance limit.

Key words Radiotherapy, Radiation-induced toxicity, Head and neck neoplasms, Ocular tolerance doses, Ocular surface, Radiation retinopathy

Introduction

Despite the serious damage to the orbit and surrounding tissues due to proximity, radiotherapy (RT) has an essential and critical role in the treatment of vascular, soft tissue, bone neoplasms in the paranasal sinus, nasal cavity, nasopharynx, and other head and neck neoplasms. The estimated radiation-induced damage to orbit has a quite wide spectrum. Ocular surface damage related with dry eye, cataract, optic neuropathy, retinopathy and even complete vision loss may develop.

Radiation retinopathy is defined as an occlusive vasculopathy secondary to the retinal vascular endothelial cell damage that results with ischemia. Radiation-induced optic neuropathy is caused by demyelination, free radical injury or DNA damage and presented with sudden, painless, irreversible visual loss after months to years following irradiation. Both are reported to have peak in 1-1.5 years, taking place between 3 months and 8 years. Radiation may cause direct damage to the corneal surface epithelium and associated erosion in the deep stromal layer, and endothelium. Keratitis sic-

ca may also develop as a result of secondary tear loss. Thus, numerous small defects develop within days and months, leading to corneal opacification, ulceration, vascularization, and eventually loss of vision [1-3].

Ocular morbidity is closely related to the proximity of the RT to the orbital tissues, the affected part, and volume in the orbital tissues and RT dose. The effects and critical dose of RT on orbital tissues are well documented in literature [3].

In this study, the potential toxicity of RT; expected to develop due to the doses taken by the optical structures, has been prospectively evaluated. The relationship between dose-volume and ocular structures was studied. The aim of this study is to investigate the functions of the anterior visual pathways with psychophysical (visual acuity, contrast sensitivity, visual field), electrophysiologic (visual evoked potentials [VEP] latency, VEP amplitude) tests in head and neck cancer patients to evaluate the radiation dose-volume effects on the cornea, lacrimal gland, retina, optic nerve and chiasm.

Correspondence: Ozlem Ozkaya Akagunduz

Department of Radiation Oncology, Ege University Faculty of Medicine, Kazimdirik, Ege Üniv. Hst. No:9, 35100 Bornova, Izmir, Turkey

Tel: 90-5335468789 Fax: 90-2323884294 E-mail: ozakagunduz@gmail.com

Received May 9, 2021 Accepted June 23, 2021

Materials and Methods

1. Patients and treatment

This prospective, cohort study included 23 patients who were treated with RT either as adjuvant after operation or curatively due to nasopharynx, paranasal sinus, and nasal cavity tumors located close to the optic structures were diagnosed in 2015-2016. Three of the patients were excluded from the study because of local recurrence, receiving the second series of RT, and one patient developing distant metastasis. A total of 19 patients were able to complete the study. According to the 2017 American Joint Committee on Cancer Staging system, 42% of the patients were stage 3. All patients were treated with volumetric arc therapy. Total RT dose to the gross tumor volume, R1 resection, R0 resection were 70 Gy, 66 Gy and 60 Gy respectively with 2.12/2.06 Gy daily fractions. The patients received 3 cycles of induction chemotherapy with cisplatin and docetaxel followed by cisplatin concomitant with RT, at 3-week intervals or concomitant weekly cisplatin or none. The details are presented in Table 1.

The patients were scanned in the supine position with a multidetector-row spiral computed tomography (CT) with a section thickness of 2 mm. On CT images, cornea, retina, lacrimal gland, retina, optic nerve, optic chiasm are defined according to the consensus guidelines of DahanCA, EORTC, GORTEC, HKNPCSG, NCIC CTG, NCRI, NRG Oncology, and TROG [4]. The anterior segment of the eyeball consists of the cornea, conjunctiva, sclera, iris, ciliary body and lens. The cornea is the clear tissue located anterior to the iris and the anterior chamber. The posterior segment of the eyeball is located posteriorly to the lens, and consists of the vitreous humor, retina and choroid. The optic nerve is excluded from this contour. On axial images the anterior limit of the retina is between the insertion of the medial rectus muscle and the insertion of the lateral rectus muscle, posterior to the ciliary body. Optic nerve has to be contoured all the way from the posterior edge of the eyeball, through the bony optic canal to the optic chiasm. The optic chiasm is located 1 cm superior to the pituitary gland. The lacrimal gland is located superolateral to the eye and lies within the preseptal space.

Dose limitations of ocular structures have been arranged according to the dose constraint guide of critical structures in five. However, since there is no definition for the lacrimal gland in this guideline, it is planned as the parotid gland. There is also no defined guideline for cornea yet, so the D_{mean} of the cornea was determined according to the previous studies in the literature [3]. Optical structures are defined as lacrimal gland $D_{\text{mean}} > 26$ Gy, retina D_{mean} and $D_{10} > 36$ Gy and 60 Gy (respectively), optic nerve and chiasm $D_{\text{max}} > 60$ Gy, cornea $D_{\text{mean}} > 40$ Gy. Received mean dose (D_{mean}) for right and left lacrimal gland, highest dose to 10% of the volume

Table 1. Patient characteristics

Characteristic	No. (%) (n=19)
Age, median (range, yr)	45 (19-70)
Sex	
Female	8 (42)
Male	11 (58)
Primary site	
Nasal cavity	8 (42)
Paranasal sinus	7 (37)
Nasopharynx	3 (16)
Skin	1 (5)
Stage	
II	6 (32)
III	8 (42)
IVA	5 (26)
Chemotherapy	
None	1 (5)
Concurrent chemoradiotherapy	16 (84)
Induction chemotherapy followed by concurrent chemoradiotherapy	2 (11)
Radiotherapy (VMAT)	
Adjuvant 60-66 Gy (2-2.06 Gy / fx)	15 (79)
Definitive 70 Gy (2.12 Gy / fx)	4 (21)
Comorbidity	
Diabetes mellitus	8 (42)
Hypertension	10 (53)
Alcohol consumption	9 (47)

VMAT, volumetric modulated arc therapy.

(D_{10}) and D_{mean} for right and left retina, D_{mean} for right and left cornea, highest dose to 5% of the volume (D_5), and maximum dose (D_{max}) for right and left optic nerve and chiasm were calculated according to the dose-volume histograms of each patient. Cutoff values were identified and the correlation between the results obtained from the ophthalmologic tests, and the values below and above the cutoff value were determined.

Patients with history of prior RT to the same region, recurrent disease, tumor invasion to the optical structures, vision loss, advanced refractive error, glaucoma, or keratitis history prior to RT and non-compliant patients were excluded.

2. Ophthalmological evaluation

Visual acuity, anterior and posterior segment evaluation, followed by visual field, contrast sensitivity, and VEP tests were performed before the RT of the patients, and after the treatment at 6th, 12th, 18th, and 24th months. The final ophthalmological examination was done at median 26 months (range, 24 to 91 months) of follow-up.

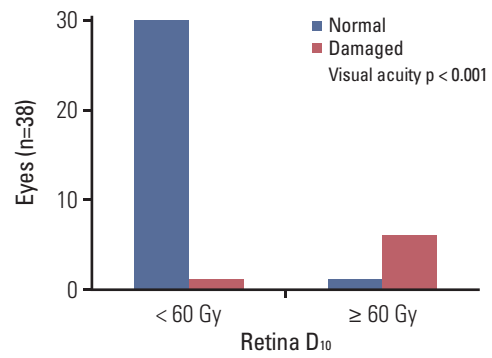
Visual acuity was measured with Snellen's chart, based

on the autorefractometer results after refractive correction. For diagnosis of dry eye disease, besides “Schirmer” and tear “Break-up Time” tests, staining of ocular surface with fluorescein was done during anterior segment examination. “Schirmer” test was performed to measure tear secretion and values above 10 mm were considered as normal. Tear film quality was assessed by tear “Break-up Time” and accepted as normal when it was higher than 10 seconds.

A full visual field (120°) test was performed with Zeiss Humphrey Field Analyser (Carl Zeiss Meditec AG, Berlin, Germany). Visual field tests reveal the functional deterioration in visual pathways as scotomas and reflects the localization of the damage. Visual field defects were scored as grade 1: normal; grade 2: peripheral defects outside the central 30°-field; grade 3: defects located in the central 30°-field; grade 4: generalized defects.

Contrast sensitivity examinations were performed by MetroVision (Monopack 3, Perenchies, France), under photopic conditions, while the patient was sitting 2 meters away from the screen, with one (the tested) eye open. The patient was asked to look at the screen, on which sinusoidal impulses with gradually increasing contrast and decreasing frequency were demonstrated and was asked to push the button in front of them when they notice the lines. Spatial frequencies between 0.5 and 15 cycle/degree were evaluated. Contrast sensitivity was scored as grade 1, normal; grade 2, under the normal line beginning from high spatial frequencies (5 cycle/degree); grade 3, under the normal line beginning from low spatial frequencies (1 cycle/degree) for each eye.

VEP were also obtained via MetroVision using pattern reversal stimulus. Three electrodes were placed on patients head, after cleaning with alcohol swab and drying the related areas, The ground electrode was placed on the forehead, reference electrode was placed on the vertex and the active electrode was placed on the occipital scalp, all located on the midline. Then, patient was asked to look at the red fixation



	Retina D ₁₀ < 60 Gy	Retina D ₁₀ ≥ 60 Gy
Visual acuity		
Normal	30 (96.7%)	1 (3.3%)
Damaged	1 (14.2%)	6 (85.7%)
p-value	< 0.001	
OR (95% CI)	6.759 (1.160-14.479)	

Fig. 1. Results of visual acuity compared between retina D₁₀ < 60 Gy and ≥ 60 Gy. CI, confidence interval; D₁₀, highest dose to 10% of the volume; OR, odds ratio.

point at the center of a black-white chekerboard patterned screen, under scotopic conditions, while the pattern reverses every half-second. The latency and amplitude of the P100 potentials for each eye was recorded in milliseconds and microvolts, respectively. VEP is the physiologic response of the visual pathway from optic nerve to occipital cortex to a visual stimulus. The normal range of VEP latency for the P100 potential is 106±3 ms, and the VEP amplitude for the P100 potential is 9±4 μV for MetroVision device. Amplitudes lower than normal and/or delay in latency is considered pathological.

Table 2. Subgroup patients who received radiotherapy above tolerance doses on optic nerve and/or eyeball

Patient (eye)	Lakrimal gland D _{mean}	Cornea D _{mean}	Retina D _{mean}	Retina D ₁₀	Optic nerve D ₅	Optic nerve D _{max}	Chiasm D _{max}
1 (right)	35	50	53	65	58	60	61
2 (left)	17	36	36	67	70	71	56
3 (right)	30	45	49	62	58	58	50
4 (right)	33	49	53	69	70	71	53
5 (left)	15	53	47	65	50	52	36
6 (right)	26	44	47	65	70	71	56
7 (right)	25	38	41	61	54	54	56
8 (right)	12	15	20	46	66	68	55

D₅, highest dose to 5% of the volume; D₁₀, highest dose to 10% of the volume; D_{max}, maximum dose; D_{mean}, mean dose.

3. Statistical analysis

PASW Statistics 18 software (SPSS Inc., Chicago, IL) was used for the statistical analysis. The significance level of α , for type I error was accepted as 0.05. The relationship between the higher and lower values of radiation dose-volume cut-off values and ophthalmologic tests was assessed using Pearson's chi-square. Fisher's exact test was used when expected numbers were less than 5 (expected frequencies). The visual acuities and VEP latency tests of patients with above tolerance doses on the eyeball and optic nerves were compared with those of patients with below tolerance doses. The risk of damage was determined by cross-tabulation odds ratio.

Results

A total of 38 eyes of 19 patients were evaluated in the study. The median age of the patients was 45 years (range, 18 to 70 years), 57% of them were male. Lens D_{max} was > 10 Gy in 58%, lacrimal gland D_{mean} was > 26 Gy in 11% of the eyes. For retina, D_{mean} and D_{10} were > 36 Gy and 60 Gy (respectively) in 18%; while for optic nerve and chiasm, D_{max} were > 60 Gy in 13% and 21% of the eyes, respectively. A decrease in contrast sensitivity and progression in visual field were observed since the beginning of RT in 42% of the patients in the last visit.

At 24th month, a decrease in visual acuity was detected in 50% of the eyes whereas a progress in visual field defect was observed in 75% of them. Contrast sensitivity was decreased 67% of the eyes, while a prolonged latency and decreased amplitude of P100 wave in VEP was observed in 58% and 33% of the eyes, respectively.

In comparison of the eight patients with eyeball and/or optic nerve radiation doses above the tolerance dose/volume (group 1) with the 11 patients with radiation doses below the tolerance dose/volume (group 2); a decrease in visual acuity was observed in six eyes (0-4/10 Snellen lines) in group 1 and in one eye in group 2 ($p < 0.001$; odds, 6.759; 95% confidence interval [CI], 1.16 to 14.47) at 36th month (Fig. 1). A prolonged latency of P100 wave in VEP was occurred in 10 eyes (110-140 ms) in group 1 versus 3 eyes in group 2 (110-115 ms) ($p=0.01$; odds, 0.12; 95% CI, 0.24 to 0.65).

Eight patients who received radiation above tolerance doses on optic nerve and eyeball (group 1) were evaluated as a subgroup (Table 2). All of these eight patients presented with dry eye symptoms of several degree. Dry eye findings started in patient No. 1 at the 3rd month, progressed in time and became severe at 12th month followed by ocular surface damage and keratitis that resulted in decreased visual acuity at the 24th month. The same patient developed cataract during follow-up. Mild dry eye symptoms occurred at the 3rd

Table 3. Subgroup patients: VA, VF, CS, and VEP tests before the radiotherapy of the patients and after the treatment at 24th month, and 36th month for VA

Patient (eye)	VA 0	VA 6	VA 12	VA 24	VA 36	VF 0	VF 24	CS 0	CS 24	VL 0	VL 24	VA 0	VA 24
1 (right)	1	0.9	0.9	0.1	NLP	2	3	2	3	120	117	5.1	3.6
2 (left)	1	1	1	0.4	0.1	2	2	2	2	105	106	12.1	10.7
3 (right)	0.8	0.7	0.4	0.3	0.1	1	3	2	3	121	128	9.5	1.7
4 (right)	1	0.8	0.8	NLP	NLP	2	-	2	-	112	128	10.7	-
5 (left)	1	0.8	NLP	NLP	NLP	1	-	1	-	109	-	4.7	-
6 (right)	0.9	0.1	0.1	NLP	NLP	1	-	1	-	103	-	3.0	-
7 (right)	1	1	1	1	0.7	1	2	1	1	103	102	8.2	6.1
8 (right)	1	1	1	1	0.8	1	1	1	1	102	103	8.5	8.5

CS, contrast sensitivity (grade); NLP, no light perception; VA, visual acuity; VEP, visual evoked potential; VF, visual field (grade).

Table 4. Subgroup patients: the ophthalmologic examination findings

Patient (eye)	Dry eye severity levels	Retinopathy	Other ocular complications	Treatment
1 (right)	Severe	-	Keratitis and cataract	Ocular lubricants, artificial tear drops, anti-inflammatory agents, and cataract surgery
2 (left)	Mild	+	Cataract	Ocular lubricants, artificial tear drops and intravitreal injection
3 (right)	Modarete	-	-	Ocular lubricants, artificial tear drops, anti-inflammatory agents
4 (right)	Modarate	+	+	Ocular lubricants, artificial tear drops, anti-inflammatory agents and intravitreal injection
5 (left)	Modarate	+	Retinal detachment	Ocular lubricants, artificial tear drops, anti-inflammatory agents, considered as inoperable
6 (right)	Severe	-	Corneal perforation	Ocular lubricants, artificial tear drops, anti-inflammatory agents and penetrating keratoplasty
7 (right)	Mild	-	-	Ocular lubricants, artificial tear drops
8 (right)	Mild	-	-	Ocular lubricants, artificial tear drops

month in patient No. 2 and both radiation-induced retinopathy and cataract were detected at the 36th month. Anterior segment disorder related with dry eye developed at the 1st month and continued during all follow-up in patient No. 3. Radiation-induced retinopathy was determined in patient No. 4 at the 24th month and moderate finding of dry eye also occurred at the 3rd month after radiation therapy. Radiation-induced retinopathy and retinal detachment developed at the 12th month; moderate dry eye occurred at the 3rd month in patient No. 5. Anterior segment damage due to severe dry eye was detected in the 6th month of patient No. 6, and then corneal perforation occurred. Mild dry eye findings occurred in patients Nos. 7 and 8 without visual loss. The detailed clinical findings of these eight patients are presented in Tables 3 and 4.

All patients who had any ocular pathology were followed and treated by ophthalmologists. Dry eye disease was treated with ocular lubricants, anti-inflammatory agents and artificial tear drops. The patient No. 6 required penetrating keratoplasty due to corneal perforation. Patient Nos. 1 and 2 underwent cataract surgery. In addition, while the patient Nos. 2 and 4 were treated with intravitreal injections for radiation retinopathy, patient No. 5 was evaluated as inoperable because of unfavorable results of retinal surgery in the eye with no light perception.

In eight of 11 patients with radiation doses below the tolerance limit (group 2), there were mild to moderate dry eye findings which responded well to topical therapy without any further complication.

Discussion

It requires a wide range of knowledge to predict which parts of the eye-related structures in the field of RT will be affected by how much RT and what kind of sequela changes may develop. However, it remains unclear due to the lack of prospective, controlled studies. In this prospective study, 38 eyes of 19 patients who had RT for head and neck tumors were followed regularly with VEP, dry eye tests and complete ophthalmological examinations. In our study, corneal perforation, keratitis and corneal opacity were observed in between 1st and 24th month, in patients with anterior segment RT dose above 40 Gy. Anterior segment damage might be caused by the direct effect of RT on cornea and conjunctiva. Limbal stem cells located at the limbus—the junction of the cornea and sclera—, play an important role in keeping the cornea transparent and in the process of renewal of the epithelium. In limbal stem cell deficiency, ocular surface damage such as basement membrane damage of the corneal epithelium in acute or chronic inflammatory processes is expected to result with superficial vascularization of the cornea [5-7]. In the literature, it is difficult to define the dose-limiting effect of radiation for corneal damage, but it has been stated that the development of punctate keratitis, edema and mild ulceration starts at 30-50 Gy RT doses [8]. However, in addition to direct damage to the cornea due to RT, secondary erosion due to dry eye might occur. Meibomian glands, as well as the lacrimal glands, are the major glands that regulate aqueous and lipid components of the tear film [9,10]. Kennerdell et al. [10] and Parsons et al. [11] reported that dry eye disease symptoms were increased over time at doses above 40 Gy in glands. Similar damage was observed

at ≥ 35 Gy ocular surface RT doses in Stafford's studies on orbital lymphomas [12]. In another study, Parsons et al. [13] reported that xerophthalmia developed when exposed to > 57 Gy, and corneal vascularization and opacification developed at these doses on the ocular surface. In our study, totally 16 patients (84.2%) developed dry eye disease. Eight patients who were the lacrimal gland $D_{\text{mean}} < 26$ Gy and cornea $D_{\text{mean}} < 40$ Gy doses had mild/moderate dry eye symptoms. They responded well to topical therapy with eye drops and visual acuities remained at the good levels. The other eight patients who were exposed to radiation above these doses presented with more severe dry eye findings and devastating complications (such as keratitis, corneal perforation) occurred despite treatment. These findings suggested that ocular surface is too vulnerable and dry eye disease may occur even with lower radiation doses. It should be noted that not only the lacrimal gland radiation dose, but also the anterior segment dose is important and it is clear that both the Meibomian glands and the limbal stem cells contribute greatly to the dry eye disease.

Radiation retinopathy is a progressive retinal vascular pathology characterized by capillary occlusion, microaneurysm formation, edema, telangiectasia, hemorrhage, retinal microvascular abnormalities and neovascularization [14-17]. As it mimics diabetic retinopathy, the presence of diabetes in radiation-induced retinopathy will contribute to the process [2,11,18]. In our study, our patients with $D_{\text{mean}} > 45$ Gy and $D_{10} > 65$ Gy developed radiation-induced retinopathy between 24 and 36 months, except for one patient. A patient with a mean retinal dose of less than 45 Gy (D_{mean} , 36 Gy) developed radiation-induced retinopathy 36 months later, suggesting that the patient's diabetes may also trigger retinopathy at lower doses of RT. Studies have also reported that RT may develop between 6 months and 3 years depending on the total dose and duration of administration [18,19]. In the study of Parsons et al. [2], retinopathy developed in almost all patients exposed to 45-55 Gy RT doses. In the study of Monroe et al. [15], 42% of the patients were treated with the hyperfractionated regimen and compared with the conventional. While retinopathy developed in two of the 13 patients with once-daily treatment with a retinal dose of 50-59 Gy, none of the 18 patients in whom RT was administered twice-daily, developed retinopathy. In the same study, retinopathy was developed in 39% and 14% of the patients, respectively at 60-69 Gy doses [15]. Considering that at least 50% of the retina volume received these doses in Parsons et al.'s study [2], and at least 25% of the retina volume in Monroe et al.'s study [15], we can conclude that the risk of retinopathy increased above 50 Gy with the conventional dose but could be partially protected with the twice-daily method. Since the anterior segment of the orbit is not a structure included in the retina, it should be evaluated separately in dose-volume

calculations. Monroe et al. [15] emphasized the importance of a 10% hotspot in such critical structures. In our study, we defined and evaluated the mean dose of the retina as well as the dose of 10% of the volume. D_{mean} defined for eyeball in the guideline prepared by Lee et al. [20] for critical organ dose constraints in nasopharyngeal carcinoma was 35 Gy and $D_{0.03\text{cm}^3} < 50$ Gy.

In the same guideline, $D_{0.03\text{cm}^3} < 60$ Gy is defined for the optic nerve. In our previous study, prolonged P100 wave latency in VEP and optic neuropathy were detected above D_{max} 60 Gy in the late period [21]. Severe radiation retinopathy and anterior segment resulted in unreliable VEP measurements with undetectable P100 wave formation, in four patients with optic nerve maximum doses over 60 Gy, in our current study.

Although the small number of patients were evaluated (due to disease progression and deaths), separate dose calculation of the anterior segment from the retina and the cut-off for the dose could be defined with examination findings and patient characteristics.

The primary limitation of this study is the low number of patients. The relapses of the disease and patient deaths resulted in a lower number of patients completing the study. Another limitation was the inability to evaluate the optic neuropathy which occurs as a late complication, in patients with keratitis and retinopathy, due to unreliable VEP tests. Despite these limitations, our study still provided valuable information about dose constraints of optical structures.

In our prospective study that we evaluate the radiation dose-volume effect with radiation-induced ocular complications, we came to the conclusion that awareness of anterior segment injury is as important as radiation-induced retinopathy. In addition to defining the volume separately from the retina, it should be known that major and minor tear glands and limbal stem cells on the corneal surface will contribute to the effect of RT. Especially for retinopathy, pre-existing systemic diseases should be known before treatment and it should be taken into consideration that lower doses may contribute to therapeutic toxicity.

Ethical Statement

Written informed consent was taken from all patients, and instructional review board approval was gathered from the Ege University Ethics Committee with protocol number 1226/474.

Author Contributions

Conceived and designed the analysis: Akagunduz OO, Yilmaz SG, Tavlayan E.

Collected the data: Akagunduz OO, Yilmaz SG, Tavlayan E, Baris ME.

Contributed data or analysis tools: Akagunduz OO, Yilmaz SG,

Afrashi F.

Performed the analysis: Akagunduz OO, Afrashi F, Esassolak M.

Wrote the paper: Akagunduz OO, Yilmaz SG, Baris ME.

Conflicts of Interest

Conflict of interest relevant to this article was not reported.

References

1. Archer DB, Amoaku WM, Gardiner TA. Radiation retinopathy: clinical, histopathological, ultrastructural and experimental correlations. *Eye (Lond)*. 1991;5(Pt 2):239-51.
2. Parsons JT, Bova FJ, Fitzgerald CR, Mendenhall WM, Million RR. Radiation retinopathy after external-beam irradiation: analysis of time-dose factors. *Int J Radiat Oncol Biol Phys*. 1994;30:765-73.
3. Jeganathan VS, Wirth A, MacManus MP. Ocular risks from orbital and periorbital radiation therapy: a critical review. *Int J Radiat Oncol Biol Phys*. 2011;79:650-9.
4. Brouwer CL, Steenbakkens RJ, Bourhis J, Budach W, Grau C, Gregoire V, et al. CT-based delineation of organs at risk in the head and neck region: DAHANCA, EORTC, GORTEC, HKN-PCSG, NCIC CTG, NCRI, NRG Oncology and TROG consensus guidelines. *Radiother Oncol*. 2015;117:83-90.
5. Sanli O, Dogru M, Erturk H. Limbal stem cells and their clinical significance. *Turkiye Klinikleri J Ophthalmol*. 2002;11:227-32.
6. Moss WT, Brand WN, Battifora H. *Radiation oncology*. 5th ed. St. Louis, MO: C.V. Mosby; 1979. p. 147-55.
7. Dua HS, Joseph A, Shanmuganathan VA, Jones RE. Stem cell differentiation and the effects of deficiency. *Eye (Lond)*. 2003;17:877-85.
8. Bomford CK. Brachytherapy. In: Bomford CK, Kunkler IH, editors. *Walter and Miller's textbook of radiotherapy*. 6th ed. Edinburgh: Churchill Livingstone; 2003. p. 225-44.
9. Karp LA, Streeten BW, Cogan DG. Radiation-induced atrophy of the Meibomian gland. *Arch Ophthalmol*. 1979;97:303-5.
10. Kennerdell JS, Flores NE, Hartsock RJ. Low-dose radiotherapy for lymphoid lesions of the orbit and ocular adnexa. *Ophthalmic Plast Reconstr Surg*. 1999;15:129-33.
11. Parsons JT, Bova FJ, Mendenhall WM, Million RR, Fitzgerald CR. Response of the normal eye to high dose radiotherapy. *Oncology (Williston Park)*. 1996;10:837-47.
12. Stafford SL, Kozelsky TF, Garrity JA, Kurtin PJ, Leavitt JA, Martenson JA, et al. Orbital lymphoma: radiotherapy outcome and complications. *Radiother Oncol*. 2001;59:139-44.
13. Parsons JT, Bova FJ, Fitzgerald CR, Mendenhall WM, Million RR. Severe dry-eye syndrome following external beam irradiation. *Int J Radiat Oncol Biol Phys*. 1994;30:775-80.
14. Suarez Baraza J, Garcia Gonzalez J, Calzado Hinojosa J, Miralles de Imperial J. Proliferative radiation retinopathy. *Arch Soc Esp Ophthalmol*. 2003;78:215-8.
15. Monroe AT, Bhandare N, Morris CG, Mendenhall WM. Preventing radiation retinopathy with hyperfractionation. *Int J Radiat Oncol Biol Phys*. 2005;61:856-64.
16. Zamber RW, Kinyoun JL. Radiation retinopathy. *West J Med*. 1992;157:530-3.
17. Anteby I, Ramu N, Gradstein L, Miskin H, Pe'er J, Benezra D. Ocular and orbital complications following the treatment of retinoblastoma. *Eur J Ophthalmol*. 1998;8:106-11.
18. Gupta A, Dhawahir-Scala F, Smith A, Young L, Charles S. Radiation retinopathy: case report and review. *BMC Ophthalmol*. 2007;7:6.
19. Durkin SR, Roos D, Higgs B, Casson RJ, Selva D. Ophthalmic and adnexal complications of radiotherapy. *Acta Ophthalmol Scand*. 2007;85:240-50.
20. Lee AW, Ng WT, Pan JJ, Chiang CL, Poh SS, Choi HC, et al. International guideline on dose prioritization and acceptance criteria in radiation therapy planning for nasopharyngeal carcinoma. *Int J Radiat Oncol Biol Phys*. 2019;105:567-80.
21. Ozkaya Akagunduz O, Guven Yilmaz S, Yalman D, Yuce B, Demirkilinc Biler E, Afrashi F, et al. Evaluation of the radiation dose-volume effects of optic nerves and chiasm by psychophysical, electrophysiologic tests, and optical coherence tomography in nasopharyngeal carcinoma. *Technol Cancer Res Treat*. 2017;16:969-77.