

Optical Coherence Tomography and Multifocal Electroretinography in Diabetic Macular Edema: A Neurovascular Relation With Vision

B.N. Nagesh, MD; Brijesh Takkar, MD; Shorya Azad, MD; Rajvardhan Azad, MD

BACKGROUND AND OBJECTIVES: To evaluate retinal neuropathy in patients with diabetic macular edema (DME) with multifocal electroretinograph (mfERG), and to evaluate the simultaneous impact of retinal neuropathy and vasculopathy on visual acuity in subtypes of DME.

PATIENTS AND METHODS: This prospective, controlled, investigative study conducted at a tertiary eye care center of Northern India included 79 eyes of 50 treatment-naïve patients with DME (Group 1), 94 eyes of 50 diabetic patients without diabetic retinopathy (Group 2), and 100 eyes of 100 normal volunteers as controls. Comprehensive ocular evaluation along with mfERG and optical coherence tomography (OCT) were performed for all patients. N1 and P1 mfERG waveforms in the two central-most rings of macula were evaluated for amplitudes and implicit time. OCT was used to sub-classify types of DME and evaluate macular thickness, ellipsoid zone (EZ), and external limiting membrane (ELM) disruption. Best-corrected visual acuity (BCVA) relative to other variables was the primary outcome measure. The three groups were compared for all the parameters inclusive of OCT and mfERG patterns. Further, OCT subtypes of DME were analyzed for mfERG waveform patterns.

RESULTS: All mfERG values were significantly lower in Group 1 and Group 2 as compared to Group 3 ($P < .05$). BCVA strongly correlated with central macular thickness, EZ, and ELM disruption scores in Group 1 ($P = .001$), but correlated modestly with mfERG waveform amplitudes in Group 1 patients with intact EZ and ELM only. BCVA correlated with mfERG amplitudes in patients with neurosensory detachment, but not in those with cystoid macular edema.

CONCLUSIONS: Neural changes set in before the clinical changes related to vasculopathy manifest in diabetic patients. Neuroretinopathy in patients with DME affects all retinal layers symmetrically in early stages, but impacts the middle retinal layers severely in advanced disease form. BCVA correlates with electrophysiological changes till the time morphological features are visible when stronger correlation is seen with anatomical disruption.

[*Ophthalmic Surg Lasers Imaging Retina*. 2016;47:626-631.]

INTRODUCTION

The human retina is composed of two types of tissue: neurological and vascular.¹ These tissues are interdependent to produce formed vision. Diabetic retinopathy (DR) affects both these tissues independently, as well as in unison.² Neurological dysfunction sets in early, whereas vasculopathy occurs at more advanced stage with clinical evidence of DR. Neuropathy occurs secondary to conduction delay due to effect of hyperglycaemia on neurotransmitters. On the other hand, vasculopathy is subsequent to damage to outer and inner retinal barrier secondary to changes due to chronic diabetes. Therefore, diabetic macular edema (DME) associated with moderate visual loss³ gives a good opportunity to study these interactions. Earlier studies have shown neuropathy to precede retinopathy and even microalbuminuria in patients with diabetes.⁴ Similarly, subclinical “neuroretinopathy” has been detected in patients without diabetes-related retinal vascular changes.⁵

Both multifocal electroretinograph (mfERG) and optical coherence tomography (OCT) have extensively studied functional and anatomical changes occurring in patients with diabetes with or without DR. mfERG is unique as it can specifically identify electric signals originating from different sections of visually sensitive pathway in the macula.^{2,6} ERG signals originating from these small sections of the macula can be then captured and analyzed in a system of rings centered on the fovea. OCT, on the other hand, is capable of generating images delineating the different layers of the choroid and retina along with the vitreoretinal interface.⁷ DME has been classified on the basis of OCT and has become an invaluable tool for follow-up and deciding retreatments.^{8,9} Hence, simultaneous interpretation of both these objec-

From the Dr. Rajendra Prasad Centre for Ophthalmic Sciences, AllMS, New Delhi-11 00 29, India (BNN, TB, AS); and the Bharti Eye Hospital, New Delhi, India (AR).

Originally submitted January 27, 2016. Revision received April 13, 2016. Accepted for publication April 27, 2016.

The authors report no relevant financial disclosures.

Address correspondence to Shorya Azad, MD, Senior Research Associate, Vitreo-Retina Services, Dr. Rajendra Prasad Centre, AllMS, New Delhi, India; email: shoryaazad@gmail.com.

doi: 10.3928/23258160-20160707-03

TABLE 1
Case Characteristics

	Group 1	Group 2	Group 3	P Value
Age (Years)	54.1+7.02	52.3+4.2	53.3 +5.8	.17
Gender (% of Males)	73.4	57.4	60.1	.07
HbA1c Level (Years)	8.19	7.28	–	.02
Duration of DM (Years)	7.9	3.3	–	< .001
BCVA (LogMAR Units)	0.569	0.027	0.005	< .001
CMT (Microns)	380.15	232.68	234.95	< .001
Macular Volume (mm Cubed)	12.3	8.9	8.7	.002
Mean EZ Disruption Score	3.8	0.12	0.07	< .001
Mean ELM Disruption Score	3.1	0.1	0.07	< .001
P1 Wave				All < .05
Amplitude 0-2 Degree Ring (nv)	942.46	1,332.5	1,536.55	
Implicit Time 0-2 Degree Ring (ms)	45.22	43.11	42.27	
Amplitude 2-5 Degree Ring (nv)	904.73	1,286.17	1,506.81	
Implicit Time 2-5 Degree Ring (ms)	45.73	43.34	42.55	
N1 Wave				All < .05
Amplitude 0-2 Degree Ring (nv)	612.53	648.59	790.13	
Implicit Time 0-2 Degree Ring (ms)	25.64	23.21	23.34	
Amplitude 2-5 Degree Ring (nv)	589.83	601.85	724.6	
Implicit Time 2-5 Degree Ring (ms)	26.07	23.41	23.49	

BCVA = best-corrected visual acuity; CMT = central macular thickness; DM = diabetes mellitus; EZ = ellipsoid zone; ELM = external limiting membrane

tive tests and their correlation to visual acuity might unearth insights into the neurological and vascular insults occurring in patients with diabetes.

Our study aims to correlate visual acuity with OCT and mfERG findings in patients of DME, including its subtypes, and diabetic patients without DR. While doing so, we attempt to establish the impact of diabetic neuropathy on DME and visual acuity and compare it with that due to anatomical changes.

PATIENTS AND METHODS

This study was conducted in accordance with the Declarations of Helsinki. The methodology of the study was approved by the ethics committee of the All India Institute of Medical Sciences, New Delhi, India. Informed consent for the investigative procedures performed was taken from all of the patients.

This was a prospective, single-center, investigative study conducted at a tertiary eye care center of northern India from July 2011 to December 2013. Treatment-naïve patients with DME who were 40 years of age or older were enrolled in the study. Age-matched, refractive

error-corrected patients without DM served as controls. Patients with any other systemic or ocular disorder affecting best-corrected visual acuity (BCVA) and those with media opacities precluding OCT examination were excluded from the study. Patients were divided into three groups. A total of 150 patients were included for analysis. Group 1 included patients with DME (79 eyes of 50 patients), Group 2 included patients with DM but no DR (94 eyes of 50 patients), and Group 3 included patients with refractive error as controls (100 eyes of 50 patients). A comprehensive ophthalmic work-up was done for all the patients along with spectral-domain OCT imaging (Cirrus; Carl Zeiss Meditec, Dublin, CA) and mfERG (Metrovision, France). Patients with proliferative DR were excluded.

OCT scans with signal strength less than 7/10 were considered unsuitable for analysis. Central macular thickness (CMT) was measured using ETDRS macular cube protocol. High-resolution cross-sectional images in both the horizontal and vertical planes passing through fovea were acquired using 5-line raster mode. A ring of 500 μ centered on the foveal midpoint was evaluated

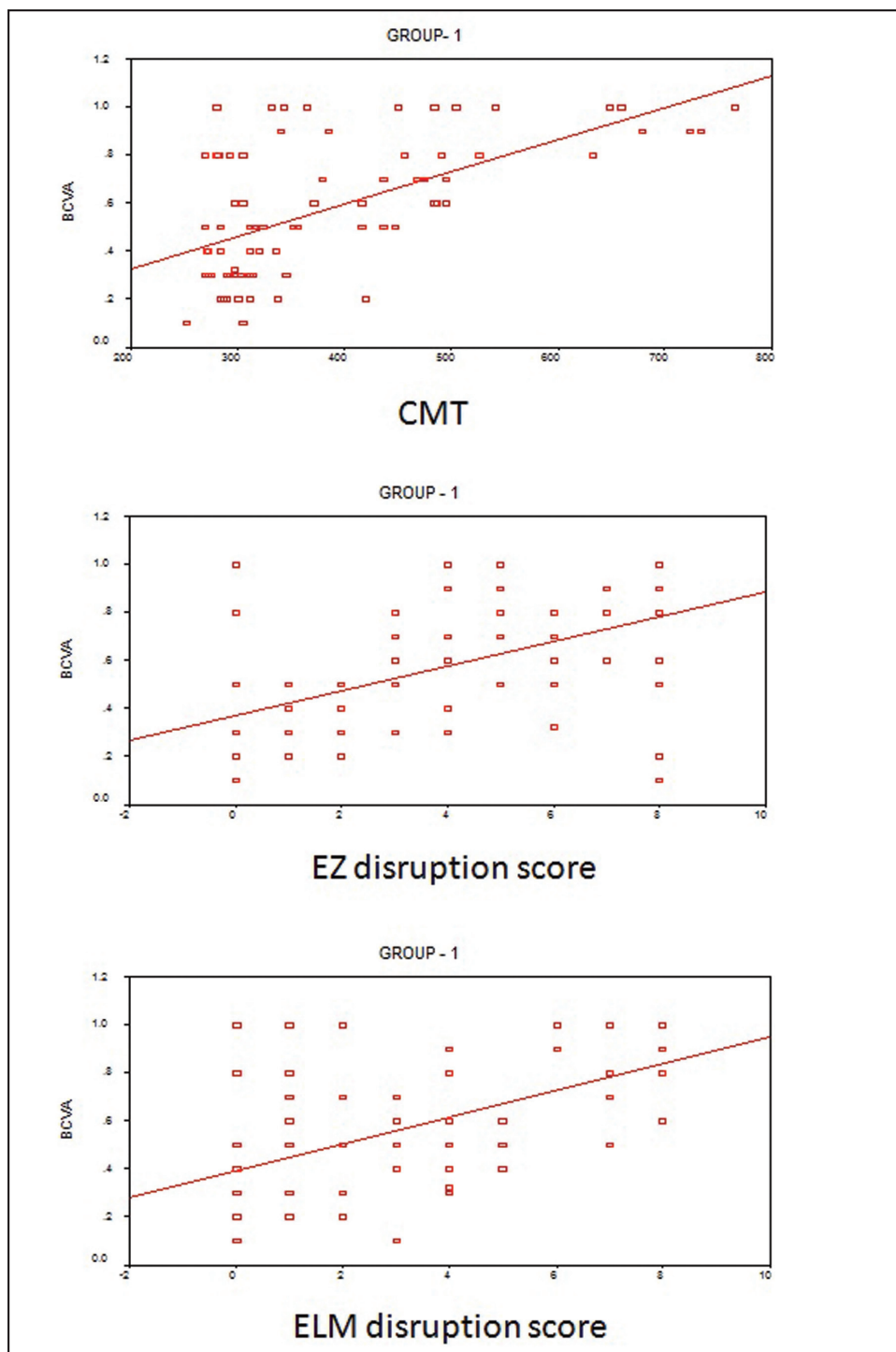


Figure 1. Scatter plots depicting correlation of visual acuity with anatomical variables.

CMT = central macular thickness; ELM = external limiting membrane; EZ = ellipsoid zone

for ellipsoid zone (EZ) disruption. EZ disruption was graded as “0” when complete EZ was found, “1” when focal disruption of the EZ less than 200 μ was noted, and “2” when more than 200 μ of disruption was noted.¹⁰ Four grades were assigned to each eye by evaluating both the horizontal and vertical meridians on either side of the midpoint separately. These four grades were

then added to yield a global disruption scale of 0 to 8 for each, where “0” represented no disruption and “8” represented total disruption on both the horizontal and vertical scans. The external limiting membrane (ELM) was analyzed in a similar way.

mfERG was performed using the 61 scaled hexagons based pattern stimulus. We measured components of

TABLE 2
Types of DME

	BCVA	Mean CMT	Mean EZ Score	Mean ELM Score	Mean P1* Amplitude	Mean P1* Implicit Time	Mean N1* Amplitude	Mean N1* Implicit Time
Cystoid (47)	0.57	384 μ	4.14	3.23	884 nv	45 ms	595 nv	26 ms
Spongiform (12)	0.43	318 μ	2.08	2.83	1187 nv	45 ms	703	26 ms
NSD (5)	0.49	321 μ	3.4	3	860 nv	46 ms	537 nv	27 ms
Mixed (12)	0.67	468 μ	5.4	3.75	835 nv	45 ms	533 nv	25 ms

*mfERG values of the central ring

BCVA = best-corrected visual acuity; CMT = central macular thickness; DME = diabetic macular edema; ELM = external limiting membrane; EZ = ellipsoid zone; mfERG = multifocal electroretinogram; NSD = neurosensory detachment; VMT = vitreomacular traction

the first order kernel of N1 and P1 waves in two concentric rings centered on the fovea in the study groups. N1 amplitude was measured from the baseline trough to the N1 trough, whereas the P1 amplitude was measured from the N1 trough to the P1 peak. Latencies of N1 and P1 waves were measured from the time of presenting the stimuli.² The resulting response can be expressed as response amplitude per unit area (nV/deg²), response density, or in simple nanovolts; we have mentioned the latter. All mfERG examinations were performed in the mydriatic state.

Analysis was done with the help of Excel (Microsoft, Redmond, WA) sheets and SPSS software version 16 (Softonic, Barcelona, Spain). Statistical tests — namely analysis of variance, Mann-Whitney, Bonferroni post-hoc test, Pearson's Chi-square test, and Spearman rank analysis — were applied for analysis. Standard formulas for mean, standard deviation, and standard error were used. A *P* value of less than .05 was taken as statistically significant.

RESULTS

The three groups were well-matched on the basis of age and gender; however, significant differences were present when comparing duration of diabetes, BCVA, CMT, macular volume, HbA1c levels, and mfERG values, which was expected (Table 1). Group 1 was characterized by longest duration of DM and higher HbA1c values. Duration of diabetes and HbA1c values had no statistical correlation with OCT or mfERG readings in either Group 1 or Group 2.

CMT, EZ disruption score, and ELM disruption score were also significantly higher in Group 1. None of these results were significant for either Group 2 or Group 3. A statistically significant correlation ($R = 0.61$) was found between CMT and BCVA ($P = .001$) in Group

1. Similarly, a strong positive relation was established between BCVA and EZ disruption score (Pearson correlation coefficient = 0.54, $P = .001$), and ELM disruption score (Pearson correlation coefficient = 0.54, $P = .001$). None of these results were significant for either Group 2 or Group 3.

Anatomically, details of variation of factors with the type of DME have been presented in Table 2. Cases with fluid beneath and inside the retina were grouped as mixed. Cystoid macular edema was the most prominent type (~60%), followed by spongiform type of DME. Statistical analysis was not done because of variable distribution of cases. Cases with cystoids macular edema had the highest CMT, worst BCVA, and worst EZ/ELM disruption scores. In contrast, spongiform edema had the lowest CMT, highest BCVA (apart from three cases of VMT), and best EZ/ELM disruption scores.

Amplitudes of both N1 and P1 waves were lowest for Group 1 in both the rings, whereas conversely, implicit times were longer; this was considered statistically significant. However, in Groups 2 and 3, these results were not significant.

mfERG amplitude for 0-2 degree ring or 2-5 degree ring did not relate significantly to visual acuity. However, in subset of patients without EZ and ELM disruption, P1 wave amplitude had a moderate relation with BCVA ($R = 0.6$, $P = .04$), as was the case with N1 wave amplitude ($R = 0.4$, $P \sim .05$). No significant relation could be established with corresponding implicit times of these waves. In patients with only neurosensory retinal detachment, the P1 wave ($R = -0.46$) and N1 wave amplitudes ($R = -0.32$) correlated significantly with BCVA ($P < .04$ in both). In patients with CME, these values were borderline insignificant ($R \sim -0.25$, $P = .06$).

On comparing with OCT findings, CMT correlated negatively with P1 wave amplitude ($R = -0.2$), whereas corresponding implicit time did not correlate with CMT. Similar results were seen for N1 wave upon being compared to CMT. Both EZ and ELM disruption scores correlated modestly with N1 and P1 wave amplitudes ($R = \sim -0.2$; $P < .05$), but not with implicit time.

Anatomically, spongiform edema also had the most favorable mfERG amplitudes. Cases with sub-retinal fluid were characterized by very low electrophysiology values. Mixed type of cases had the most unfavorable electrophysiological results (Table 2).

DISCUSSION

Utility of mfERG in DR has been well-evaluated, with studies reporting early changes without clinical evidence of DR.^{11,12} In fact, mfERG has been used to predict onset of new diabetic retinopathy in patients with nonproliferative disease.^{13,14} Increased implicit time has been found to be more useful than amplitude of the mfERG waveform.^{12,14} Other studies have correlated macular thickness in patients with DME to mfERG patterns in pursuit of analyzing both functional and anatomical aspects.¹⁵ Patients with DME, especially those with hard exudates, have been found to have diminished mfERG implicit time and reduced amplitudes.^{16,17,18} Similarly, the effect of laser photocoagulation, surgery, and intravitreal injections in DME has been studied with mfERG.^{19,20,21} Literature, however, lacks in electrophysiological evaluation of the types of DME. As most of the clinical parameters and mechanisms vary between types of DME, simultaneous evaluation of OCT and mfERG offers an entirely new perception. The limited available data in this regard (literature search done with keywords inclusive of “DME,” “OCT,” and “mfERG”) report the N1 wave to be a stronger indicator than the P1 wave in CME.²²

BCVA does not always correlate with macular changes (including OCT-based architecture) in patients with DME.² Recent interest in mfERG analysis of patients of DME tries to solve this ambiguity by assessing DME as both a neuropathy and angiopathy.^{2,16} No overall relation was established between mfERG and BCVA in Group 1 patients, whereas a moderate correlation of borderline significance was established in Group 1 patients with continuous EZ/ELM. Therefore, in the setting of morphological changes in the outer retina, BCVA did not relate to mfERG; similar findings have been reported in previous studies.⁵

Electrophysiology changes are proven to proceed retinal nerve fiber layer (RNFL) and perimetric changes,²³ and it is well-established that mfERG changes do not relate with RNFL changes.²⁴ Although our results could be due to associated effect on the innermost retinal layers, which have not been studied separately, we believe that the differing effects of “neuroretinopathy” and retino-vasculopathy on visual acuity may also contribute to these results.

In the same direction, our study found poorer electrophysiology in patients with neurosensory retinal detachment (NSD), although architectural changes and vision loss were more associated with CME. The N1 and P1 waves originate from photoreceptors and muller/bipolar cells, respectively.² Therefore, it appears that patients with NSD are more affected by “neuropathy,” whereas in CME, the visual changes are more contributed to the mechanical insult. These results are further consolidated by the significant correlation between BCVA and N1/P1 amplitudes seen in patients with NSD. Though bipolar cells are stretched in CME, such a significant correlation could not be established in those patients. However, unlike in a previous study,² we could not establish similar results for implicit times of the individual wave forms for any of the groups. A previous study from China of 24 patients with CME, possibly of multifactorial origin, found a stronger association between mfERG responses and visual acuity. We had included 47 patients with diabetic CME and could establish only borderline association.

In contrast to our study, previously published results have found good correlation between BCVA, morphological changes, and functional changes.²⁵ However, this study did not include patients with serous retinal detachment, had used time-domain OCT, and the authors also concluded a better relation between BCVA and CMT. BCVA and mfERG.²⁵ In contrast, another study conducted in Iran found better relation between visual acuity and mfERG response rather than CMT.² This study does not analyze the type of DME included.²

The photoreceptors are completely dependent on choroidal vasculature for metabolism and the bipolar cells are at the watershed region. Therefore, one may assume the N1 wave to be less affected than the P1 wave in DR, which is known to affect the middle retina the most.²⁶ P1 wave amplitudes in our study were reduced to 60% in Group 1 (assuming Group 3 to be baseline), whereas N1 wave amplitudes were reduced to 80%. Hence, the ultimate effect of the vasculopa-

thy is more on the middle order cells than first order cells. However, in Group 2 the effect was similar for both the waves. Therefore, the effect of hyperglycemia is equal across the retinal layers until DME sets in clinically when the ischemic insult is specifically borne by the middle layers. Between CME and NSD, the change in N1 wave amplitude was much more pronounced in NSD than the P1 wave, which was equivalent in both. This underlines the outer retinal barrier breakdown in NSD.

Like previous studies, we found spongiform edema and CME to be commoner than NSD. We also found deranged electrophysiology in the central macula in patients without DR, as noted before. However, we could not evaluate the inner retinal changes which would have contributed to visual changes, especially in patients with CME. Also, we could not establish a relation of mfERG implicit time with other variables, though previous results in this regard are controversial.² It should be remembered that in the presence of large cystoid spaces, OCT-based EZ and ELM maybe incorrect. Thus, interpretations regarding the outer retinal/photoreceptor integrity may be hampered.

To conclude, diabetic neuroretinopathy sets in before the clinical manifestations of the vasculopathy. Visual acuity correlates well anatomical changes, though modest correlation with electrophysiology is seen in patients with preserved retinal architecture. NSD is associated with electrophysiological changes, whereas CME is more associated with mechanical changes. In its neuroretinopathy stage, DR affects the retinal neurons equally, whereas in its clinical state, middle retinal layers are severely impacted.

REFERENCES

1. Foos RY. Chronic retinopathy of prematurity. *Ophthalmology*. 1985;92(4):563-574.
2. Tehrani NM, Riazi-Esfahani H, Jafarzadehpur E, et al. Multifocal electroretinogram in diabetic macular edema; correlation with visual acuity and optical coherence tomography. *J Ophthalmic Vis Res*. 2015;10(2):165-171.
3. No authors listed. Treatment techniques and clinical guidelines for photocoagulation of diabetic macular edema. Early Treatment Diabetic Retinopathy Study Report Number 2. *Ophthalmology*. 1987;94(7):761-774.
4. Petropoulos IN, Green P, Chan AWS, et al. Corneal confocal microscopy detects neuropathy in patients with Type 1 diabetes without retinopathy or microalbuminuria. *PLoS ONE*. 2015;10(4):e0123517.
5. Adams AJ, Bearse MA Jr. Retinal neuropathy precedes vasculopathy in diabetes: a function-based opportunity for early treatment intervention? *Clin Exp Optom*. 2012;95(3):256-265.
6. Hood DC, Bach M, Brigell M, et al. ISCEV standard for clinical multifocal electroretinography (mfERG) (2011 edition). *Doc Ophthalmol*. 2012;124(1):1-13.
7. Staurengi G, Sadda S, Chakravarthy U, et al. Proposed lexicon for anatomic landmarks in normal posterior segment spectral-domain optical coherence tomography: the IN•OCT consensus. *Ophthalmology*. 2014;121(8):1572-1578.
8. Panozzo G, Parolini B, Gusson E, et al. Diabetic macular edema: an OCT-based classification. *Semin Ophthalmol*. 2004;19(1-2):13-20.
9. Panozzo G, Gusson E, Parolini B, et al. Role of OCT in the diagnosis and follow up of diabetic macular edema. *Semin Ophthalmol*. 2003;18(2):74-81.
10. Maheshwary AS, Oster SF, Yuson RM, Cheng L, Mojana F, Freeman WR. The association between percent disruption of the photoreceptor inner segment-outer segment junction and visual acuity in diabetic macular edema. *Am J Ophthalmol*. 2010;150(1):63-67.e1.
11. Shimada Y, Li Y, Bearse MA Jr., Sutter EE, Fung W. Assessment of early retinal changes in diabetes using a new multifocal ERG protocol. *Br J Ophthalmol*. 2001;85(4):414-419.
12. Fortune B, Schneck ME, Adams AJ. Multifocal electroretinogram delays reveal local retinal dysfunction in early diabetic retinopathy. *Invest Ophthalmol Vis Sci*. 1999;40(11):2638-2651.
13. Han Y, Bearse MA Jr., Schneck ME, Barez S, Jacobsen CH, Adams AJ. Multifocal electroretinogram delays predict sites of subsequent diabetic retinopathy. *Invest Ophthalmol Vis Sci*. 2004;45(3):948-954.
14. Ng JS, Bearse MA Jr., Schneck ME, Barez S, Adams AJ. Local diabetic retinopathy prediction by multifocal ERG delays over 3 years. *Invest Ophthalmol Vis Sci*. 2008;49(4):1622-1628.
15. Kang H1, Xu YS, Zhang H, Du B. Characters of multifocal electroretinogram in different grades of diabetic macular edema. *Zhonghua Yan Ke Za Zhi*. 2011;47(8):709-714.
16. Bearse MA Jr., Ozawa GY. Multifocal electroretinography in diabetic retinopathy and diabetic macular edema. *Curr Diab Rep*. 2014;14(9):526.
17. Schneck ME, Bearse MA Jr., Han Y, Barez S, Jacobsen C, Adams AJ. Comparison of mfERG waveform components and implicit time measurement techniques for detecting functional change in early diabetic eye disease. *Doc Ophthalmol*. 2004;108(3):223-230.
18. Greenstein VC, Holopigian K, Hood DC, Seiple W, Carr RE. The nature and extent of retinal dysfunction associated with diabetic macular edema. *Invest Ophthalmol Vis Sci*. 2000;41(11):3643-3654.
19. Venkatesh P, Ramanjulu R, Azad R, Vohra R, Garg S. Subthreshold micropulse diode laser and double frequency neodymium: YAG laser in treatment of diabetic macular edema: a prospective, randomized study using multifocal electroretinography. *Photomed Laser Surg*. 2011;29(11):727-733.
20. Kim YM, Lee SY, Koh HJ. Prediction of postoperative visual outcome after pars plana vitrectomy based on preoperative multifocal electroretinography in eyes with diabetic macular edema. *Graefes Arch Clin Exp Ophthalmol*. 2010;248(10):1387-1393.
21. Durukan AH, Memisoglu S, Gundogan FC. Is multifocal ERG a reliable index of macular function after triamcinolone acetonide injection in diffuse diabetic macular edema? *Eur J Ophthalmol*. 2009;19(6):1017-1027.
22. Wu D, Jiang F, Liang J, et al. Multifocal electroretinogram in cystoid macular edema. *Yan Ke Xue Bao*. 2003;19(4):253-256.
23. Lung JC, Swann PG, Wong DS, Chan HH. Global flash multifocal electroretinogram: early detection of local functional changes and its correlations with optical coherence tomography and visual field tests in diabetic eyes. *Doc Ophthalmol*. 2012;125(2):123-135.
24. Dale EA, Hood DC, Greenstein VC, Odel JG. A comparison of multifocal ERG and frequency domain OCT changes in patients with abnormalities of the retina. *Doc Ophthalmol*. 2010;120(2):175-186.
25. Yamamoto S, Yamamoto T, Hayashi M, Takeuchi S. Morphological and functional analyses of diabetic macular edema by optical coherence tomography and multifocal electroretinograms. *Graefes Arch Clin Exp Ophthalmol*. 2001;239(2):96-101.
26. Tripathy K, Sharma YR, R K, et al. Recent advances in management of diabetic macular edema. *Curr Diabetes Rev*. 2015;11(2):79-97.