

Functional and high resolution retinal imaging assessment in a case of ocular siderosis

Céline Faure · Kiyoko Gocho · Yannick Le Mer ·
José Alain Sahel · Michel Paques · Isabelle Audo

Received: 6 June 2013 / Accepted: 5 December 2013 / Published online: 13 December 2013
© Springer-Verlag Berlin Heidelberg 2013

Abstract

Purpose To report new findings in a case of ocular siderosis explored by high resolution angiography and adaptive optics (AO).

Methods We report data on a 40-year-old man with an intraocular foreign body (IOFB) embedded in the sclera after hammering.

Results Nine months after this accident, the patient presented with full-field electroretinogram (FF-ERG) abnormalities. Subsequent IOFB extraction was performed. One month after the surgery, high resolution angiography showed for the first time small iron particles all over the inner retinal surface. Spreading of these deposits was followed by inflammatory prepapillary new vessels and venous retinal vasculitis, which spontaneously resolved within a few months. ERG

responses became slightly electronegative at this time. Clearance of the iron particles was followed over a year with AO and ERG recording. AO revealed an arterial tropism with a decrease in the amount of particles overtime, which may be consistent with macrophagic activity.

Conclusion High resolution angiography and AO are new tools, combined with electrophysiology, to better understand ocular siderosis pathophysiology.

Keywords Ocular siderosis · Electronegative ERG · Iron deposit · Inflammatory prepapillary new vessels · Adaptive optics

Introduction

Ocular siderosis is a sight-threatening complication of iron-containing intraocular foreign bodies (IOFB) [1].

This article presented at a conference, poster at ARVO 2012.

C. Faure (✉) · Y. Le Mer · J. A. Sahel
Fondation ophtalmologique Adolphe de Rothschild,
25 rue Manin, 75019 Paris, France
e-mail: celinefaureoph@gmail.com

K. Gocho · J. A. Sahel · M. Paques · I. Audo
Centre Hospitalier National d'Ophtalmologie des
Quinze-Vingts, INSERM-DHOS CIC 503, 75012 Paris,
France

J. A. Sahel
Unité d'électrophysiologie, Centre Hospitalier National des
Quinze-Vingts, 28 rue de Charenton, 75012 Paris, France

J. A. Sahel · M. Paques · I. Audo
INSERM, U968, 75012 Paris, France

J. A. Sahel · M. Paques · I. Audo
UPMC Univ Paris 06, UMR_S 968, Institut de la Vision,
75012 Paris, France

J. A. Sahel · M. Paques · I. Audo
CNRS, UMR_7210, 75012 Paris, France

It may occur weeks to years after ocular injury [2]. Clinical signs of ocular siderosis for the anterior segment include iris heterochromia, mydriasis, cataract, lens subluxation, uveitis, and secondary glaucoma [3, 4]. Posterior pole involvement may manifest with early optic disk hyperemia, cotton-wool spots, and fluorescein angiographic leakage. Later, peripheral pigmentary clumping and severely reduced retinal sensitivity on visual field test may occur [5–7].

Little is known on transformation of IOFB and its redistribution within ocular tissues. The natural course of a retained intraocular iron foreign body is variable, and the only way of prevention is its removal, which is not always possible without major postsurgical complication. Full-field electroretinogram (FF-ERG) is the most common means for detecting ocular siderosis. The early stages of siderosis are characterized by a preserved a-wave and reduced b-wave in response to a bright flash under scotopic conditions (electronegative waveform). These changes suggest primary inner

retinal abnormalities (b-wave) induced by iron toxicity prior to disturbance at the photoreceptor level (secondary a-wave reduction) [8].

In some cases, the foreign body may become encapsulated and the siderosis may stabilize or regress. Therefore, when the IOFB is deeply embedded in ocular tissues with difficult surgical removal, careful follow-up of retinal function by FF-ERG is required.

Here, we present a case of iron-containing IOFB that was followed up over 2 years. The patient showed initial outer retinal dysfunction together with retinal vasculitis that worsened postoperatively possibly because of iron dispersion as assessed by adaptive optics (AO).

Case report

A 40-year-old man presented to us with an iron-containing subretinal foreign body IOFB embedded

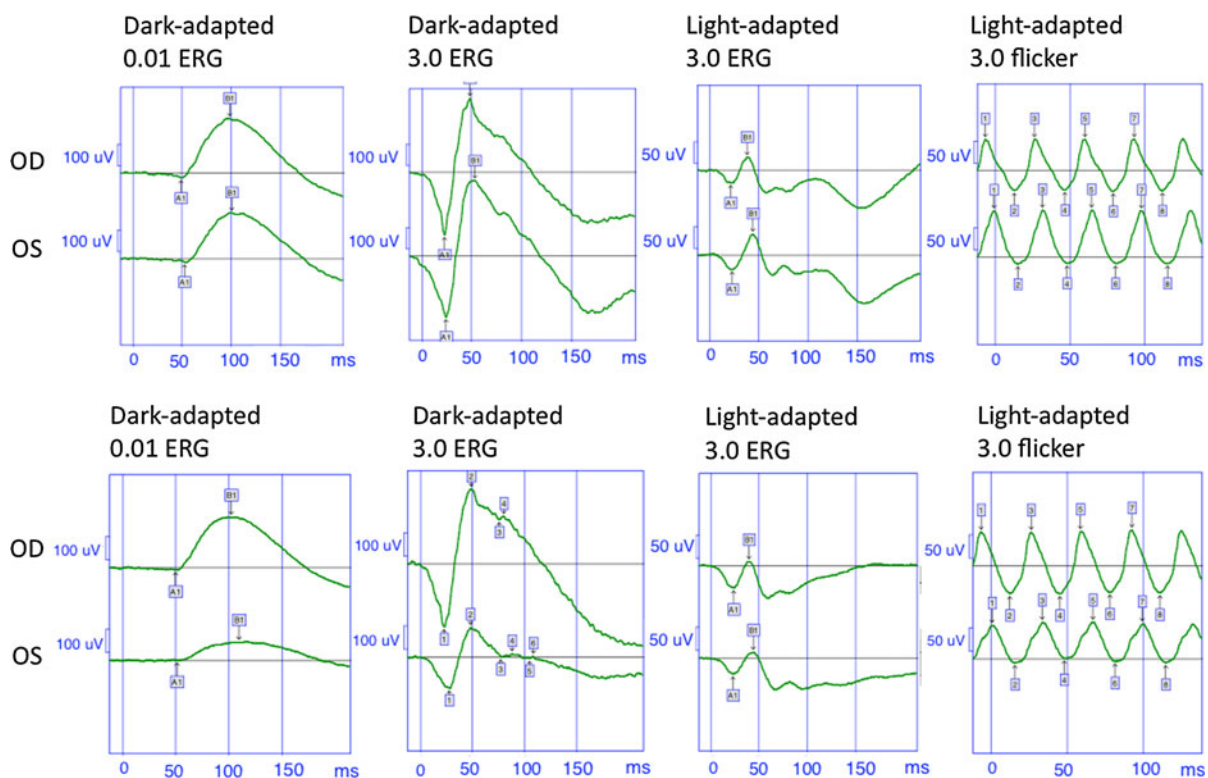


Fig. 1 Initial full-field ERG, 2 months after the accident, is recorded with contact lens electrodes with the MetrovisionTM set-up, Perenchies, France (*top*). The right eye (first trace) shows a representative normal control. There is a slight implicit time

shift in the flicker response of the left eye (*second trace*). Nine months after the accident (*bottom traces*), a global decrease in amplitudes is present that may be in keeping with an early alteration at the level of the photoreceptors

into the sclera in the left eye after hammering. Best corrected visual acuity (BCVA) of his left eye was 20/20 at presentation. Since the IOFB was very posterior and difficult to extract, laser impacts were applied around it and close follow-up was decided. A

first full-field ERG according to the ISCEV standard [9] and using contact lens electrodes was recorded 2 months after the accident (Fig. 1, recordings performed with the Metrovision™ set-up, Perenchies, France). This showed a slight implicit time shift in the

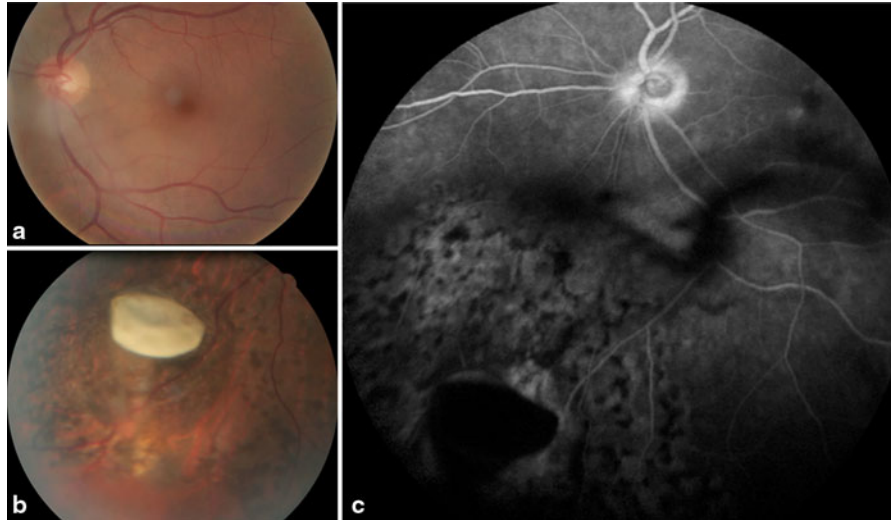


Fig. 2 (a) Color fundus photographs of the left posterior pole with mild vitritis. (b) Color picture showing the foreign body embedded in the ocular wall. (c) Fluorescein angiography

showing a diffuse disruption of the hemato-retinal barrier with papillitis and a mild vitritis. IOFB is embedded into the sclera inferonasally to the optic nerve

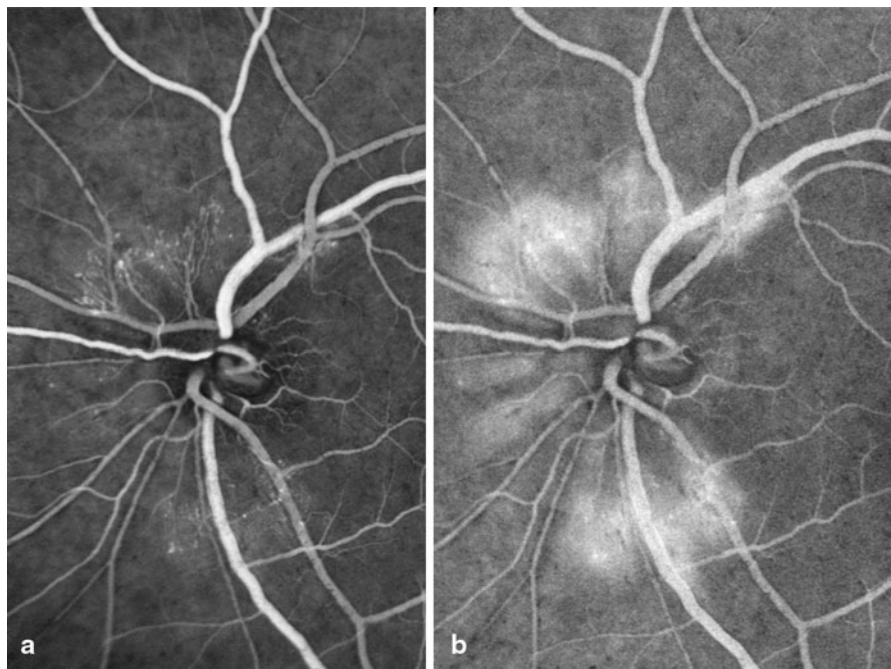


Fig. 3 Fluorescein angiography 4 months after IOFB removal showing prepapillary new vessels in the early phase (a) with diffusion in the late phase (b)

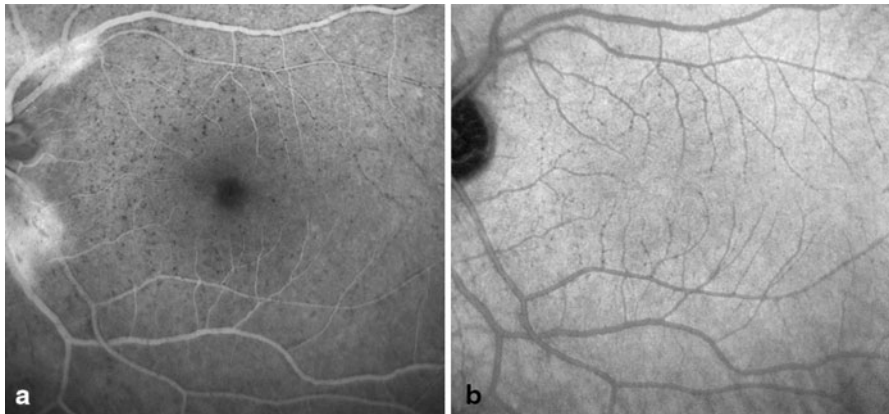


Fig. 4 Late stage of fluorescein (a) and indocyanine green angiography (b) showing iron particles after IOFB removal

flicker response under photopic conditions with no other abnormalities.

Nine months after the accident, left eye BCVA was still 20/20. However, the patient started to develop a mild vitritis with optic disk leakage on FA (Fig. 2). Full-field ERG was repeated on the same setup and showed moderate decreased and delayed responses under both scotopic and photopic conditions that may be in keeping with mild generalized photoreceptor dysfunction or secondary to the mild vitritis (Fig. 1). Following the electrophysiological findings, IOFB was removed by vitrectomy. Laboratory analysis confirmed the iron nature of the foreign body.

The subject maintained 20/20 BCVA during follow-up. Four months after the surgery, disseminated iron deposits, predominantly along arterioles, and prepapillary new vessels were present (Figs. 3, 4). Prepapillary new vessels spontaneously disappeared within 6 months (Fig. 5). However, new areas of venous vascular leakage were seen on FA (Fig. 5). One year after IOFB removal, full-field ERG (this time recorded with DTL electrodes using the Espion 3 setup, Diagnosys LLC, Cambridge, UK) became slightly electronegative (Fig. 6). Four months after the surgery, AO imaging (rtx1 camera, Imagine Eyes, Orsay, France) showed the location of iron particles at the inner retinal surface with a perivascular, mostly arteriolar, distribution (Fig. 7). Six months and 12 months later, AO showed a decrease in the number of particles and a modification of their localization (Fig. 8).

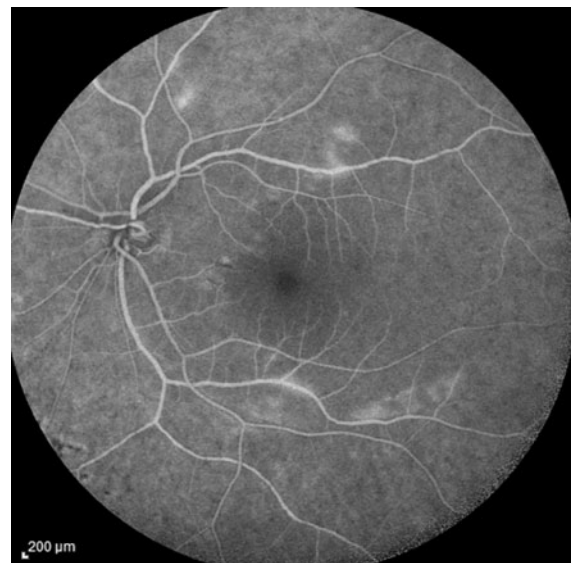


Fig. 5 Ten months after the surgery, fundus fluorescein angiogram of the left eye reveals patchy capillary non-perfusion areas with small retinal hemorrhages in the interpapillomacular region. The prepapillary new vessels have disappeared within 6 months

Discussion

Several factors are reported to affect the prognosis of ocular siderosis caused by IOFB: way of entry into the eye, physical and chemical nature, size, location, and formation of encapsulation [10].

Intraocular foreign body is most of the time located in the vitreous cavity. In these situations, iron is thought to penetrate into the retina from the internal

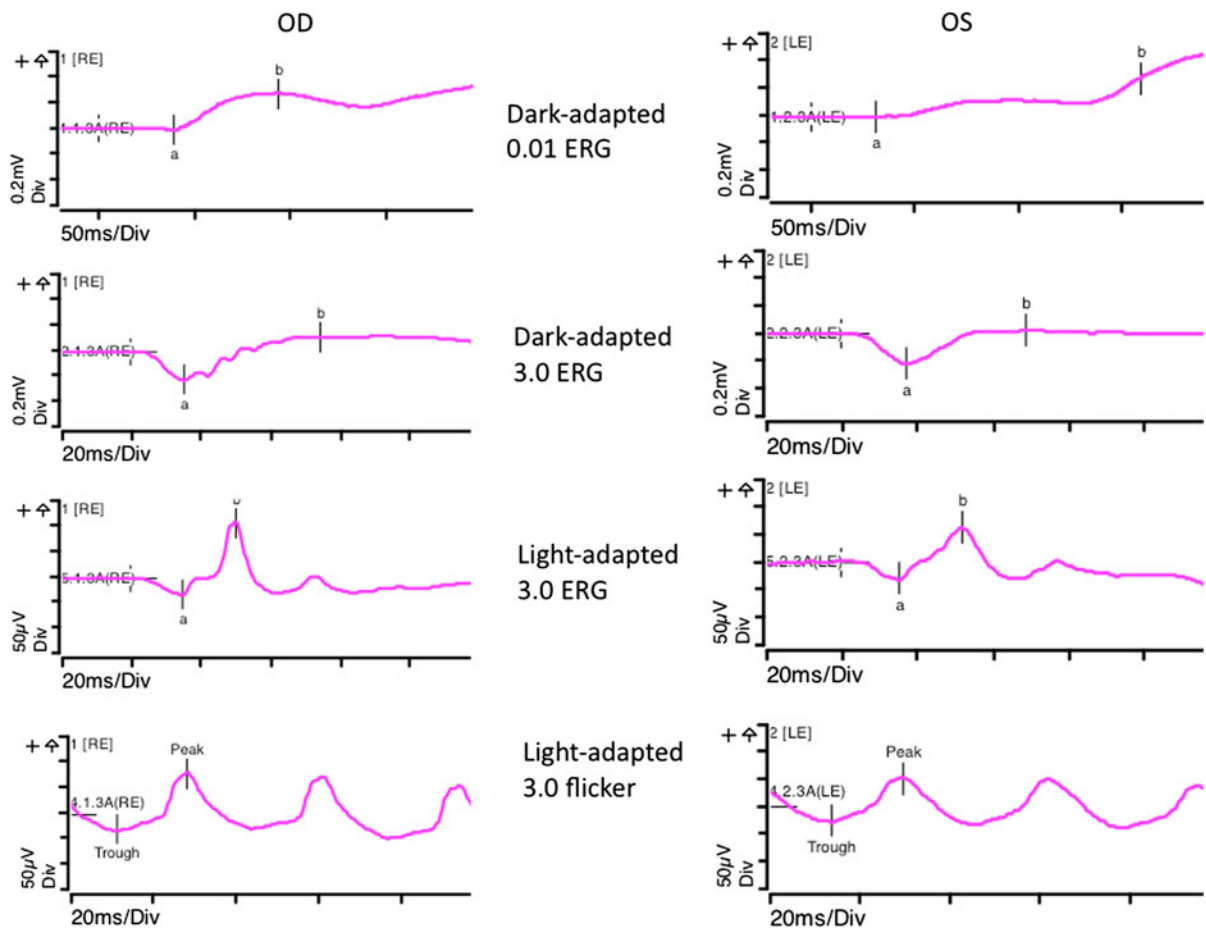


Fig. 6 Full-field ERG 16 months after IOBF removal, recorded with DTL electrodes using the Espion 3 set-up (Diagnosys LLC, Cambridge, UK), showed a slightly electronegative wave formed of the dark-adapted 3.0 ERG response

side along Muller cells, explaining why the degeneration process primarily affects inner retinal layers before reaching photoreceptor layer [11]. Therefore, at the early stages of siderosis, ERG responses showed a normal a-wave while the b-wave can be reduced in amplitude on the dark-adapted mixed response (electronegative ERG). Rod-dominated responses are predominantly affected. The differential effect of siderosis on cone- and rod-ERG responses may be attributed to a greater susceptibility to iron toxicity of the rod system compared to the cone system [8].

As siderosis progresses, responses are progressively reduced in amplitude to become eventually undetectable [7, 8]. The same findings are reported in experimental siderosis in rabbits and human histopathologic specimens [1, 12].

In case of severe intraocular inflammation, external retinal layers can be involved in the early stages of ocular siderosis [11]. In our case, the subretinal location of the IOFB may have induced a generalized inflammatory response that could explain the early alteration of the a-wave amplitude. After IOFB removal, vascular changes and the spread of iron particles predominate in inner layers with b-wave amplitude and b/a ratio reduction. This could suggest that in siderosis, both inflammation and direct iron toxicity may participate to the variability of the ERG findings at presentation.

Histopathologic studies showed that iron granules were present in all retinal layers but mostly in macrophages [11]. Moreover, retinal pigment epithelial cells in the affected area were larger than normal,

Fig. 7 (a) Optical coherence tomography scan with location of the area of AO picture taken 4 months after the surgery. AO imaging showing iron deposits located at the inner retinal surface (b) with vascular tropism. Cones can be seen at the level of the outer retina (c)


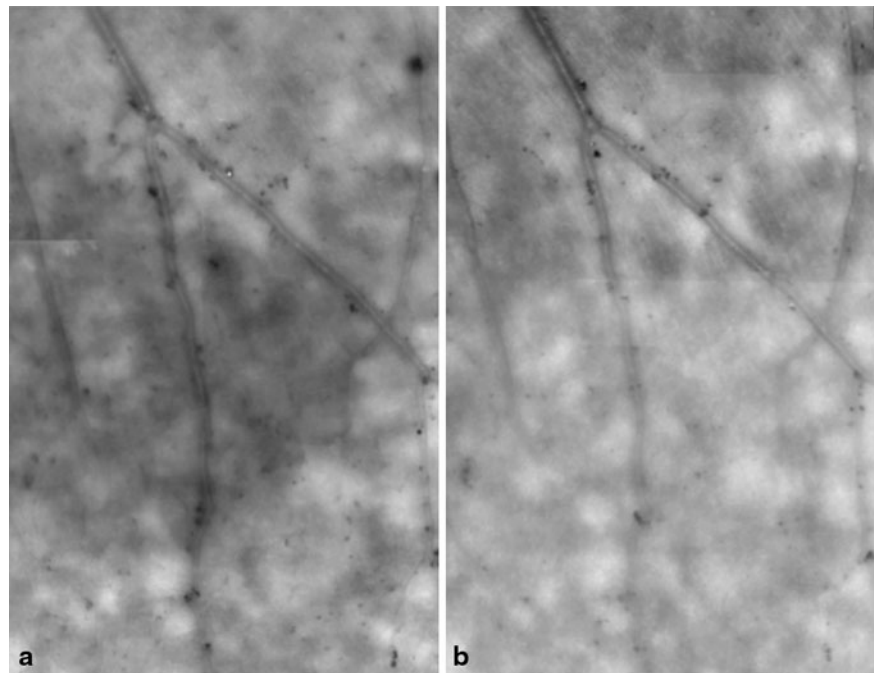


Fig. 8 AO imaging repeated at 6 (a) and 12 months (b) later with decreased amount and modification in pattern distribution of the iron particles



and some of them had migrated into the sensory retina, indicating an increased phagocytic role [1]. In our patient, AO revealed a vascular tropism of iron deposits with a decrease amount of particles overtime, which may confirm this macrophagic activity. Ocular siderosis is thought to be reversible up to a decrease of

40 % in ERG b-wave amplitude [13]. Over this limit, macrophagic activity may be overwhelmed by the amount of iron load leading to direct cellular toxicity. Progress in retinal imaging allows us to visualize for the first time the postoperative spread of small irons particles on fluorescein and ICG angiography,

especially at the late phase. This secondary release of particles can induce postoperative functional worsening.

Electroretinogram recordings remain the reference follow-up exam in case of IOFB, especially since after the surgery, as our case illustrate, many small particles can be released at the inner retinal surface potentially inducing further toxicity. High resolution imaging technique such as AO can be a useful tool at this point for precise monitoring of clearance of the deposits.

Conflict of interest None.

References

1. Declercq SS, Meredith PC, Rosenthal AR (1977) Experimental siderosis in the rabbit: correlation between electroretinography and histopathology. *Arch Ophthalmol* 95(6): 1051–1058
2. O'Duffy D, Salmon JF (1999) Siderosis bulbi resulting from an intralenticular foreign body. *Am J Ophthalmol* 127(2): 218–219
3. Janssens D, Libert J (1999) Anatomic-clinical study of two cases of ocular siderosis. *Bull Soc Belge Ophtalmol* 272: 115–119
4. Sangermani C, Mora P, Mancini C, Vecchi M, Gandolfi SA (2010) Ultrasound biomicroscopy in two cases of ocular siderosis with secondary glaucoma. *Acta Ophthalmol* 88(1):e1–e2
5. Shaikh S, Blumenkranz MS (2001) Fluorescein angiographic findings in ocular siderosis. *Am J Ophthalmol* 131(1):136–138
6. Cleary G, Sheth HG, Laidlaw AH (2007) Delayed transient macular ischaemia due to ocular siderosis. *Eye (Lond)* 21(8):1132–1133 Epub 2007 Jun 15
7. Sieving PA, Fishman GA, Alexander KR, Goldberg MF (1983) Early receptor potential measurements in human ocular siderosis. *Arch Ophthalmol* 101(11):1716–1720
8. Schechner R, Miller B, Merksamer E, Perlman I (1990) A long term follow up of ocular siderosis: quantitative assessment of the electroretinogram. *Doc Ophthalmol* 76(3): 231–240
9. Marmor MF, Fulton AB, Holder GE, Miyake Y, Brigell M, Bach M (2009) International Society for Clinical Electrophysiology of Vision. ISCEV Standard for full-field clinical electroretinography (2008 update). *Doc Ophthalmol* 118(1):69–77
10. Tanabe J, Shirao Y, Oda N, Kawasaki K (1992) Evaluation of retinal integrity in eyes with retained intraocular metallic foreign body by ERG and EOG. *Doc Ophthalmol* 79(1):71–78
11. Appel I, Barishak YR (1978) Histopathological changes in siderosis bulbi. *Ophthalmologica* 176(4):205–210
12. Tawara A (1986) Transformation and cytotoxicity of iron in siderosis bulbi. *Invest Ophthalmol Vis Sci* 27(2):226–236
13. Weiss MJ, Hofeldt AJ, Behrens M, Fisher K (1997) Ocular siderosis. Diagnosis and management. *Retina* 17(2):105–108