

See discussions, stats, and author profiles for this publication at: <https://www.researchgate.net/publication/235769761>

# Anwar versus Melles Deep Anterior Lamellar Keratoplasty for Keratoconus A Prospective Randomized Clinical Trial

Data · March 2013

CITATIONS

5

READS

91

5 authors, including:



[Alireza Baradaran- Rafii](#)

Shahid Beheshti University of Medical Sciences

75 PUBLICATIONS 1,239 CITATIONS

[SEE PROFILE](#)



[mohammad mehdi Sadoughi](#)

Shahid Beheshti University of Medical Sciences, Ophthalmic research center

14 PUBLICATIONS 276 CITATIONS

[SEE PROFILE](#)



[Hamed Esfandiari](#)

Shahid Beheshti University of Medical Sciences

95 PUBLICATIONS 246 CITATIONS

[SEE PROFILE](#)

Some of the authors of this publication are also working on these related projects:



TransPRK Research Group; Universal Council of Ophthalmology [View project](#)



comparison of phakic IOLs [View project](#)

# Anwar versus Melles Deep Anterior Lamellar Keratoplasty for Keratoconus

## A Prospective Randomized Clinical Trial

Alireza Baradaran-Rafii, MD,<sup>1</sup> Medi Eslani, MD,<sup>1,2</sup> Mohammad-Mehdi Sadoughi, MD,<sup>1</sup>  
Hamed Esfandiari, MD,<sup>1</sup> Farid Karimian, MD<sup>1</sup>

**Purpose:** To compare the outcomes of 2 techniques (Anwar vs. Melles) of deep anterior lamellar keratoplasty (DALK) in patients with keratoconus.

**Design:** Randomized, double-blind clinical trial.

**Participants:** Fifty-seven eyes of 57 patients 20 to 35 years of age were enrolled.

**Methods:** Patients with clinical diagnosis of keratoconus who were contact lens intolerant and whose corrected distance visual acuity (CDVA) was less than 20/80 were enrolled. Eligible eyes were allocated randomly into 2 groups: the Anwar technique (23 eyes) or the Melles technique (25 eyes).

**Main Outcome Measures:** The primary outcome measure was CDVA. Secondary outcomes were spherical equivalent, contrast sensitivity, corneal aberrations, corneal biomechanical properties, endothelial cell count, and central corneal thickness. All outcomes were compared 15 months after surgery.

**Results:** The CDVA was  $0.17 \pm 0.09$  logarithm of the minimum angle of resolution (logMAR) units and  $0.18 \pm 0.11$  logMAR units in the Anwar and Melles groups, respectively ( $P = 0.803$ ). Spherical equivalent was  $-1.82 \pm 2.7$  diopters (D) and  $-2.69 \pm 3.94$  D in the Anwar and Melles groups, respectively ( $P = 0.155$ ). Overall, the difference in photopic and mesopic contrast sensitivity function between the 2 groups was statistically significant ( $P < 0.05$ ). There was no significant difference between 2 groups in total and higher-order aberrations up to the fifth order ( $P > 0.05$  for all parameters). Corneal hysteresis was not significantly different between the 2 groups ( $9.9 \pm 0.8$  vs.  $9.9 \pm 0.6$ ;  $P = 0.606$ ). The corneal resistance factor was  $10.02 \pm 0.8$  and  $10.13 \pm 0.76$  ( $P = 0.509$ ). There was no significant difference in percentage of endothelial cell loss between the 2 groups ( $1 \pm 2\%$  vs.  $1 \pm 3\%$  in the Anwar and Melles groups, respectively;  $P = 0.869$ ). Mean central corneal thickness was  $525.56 \pm 47.87 \mu\text{m}$  versus  $504.64 \pm 54.20 \mu\text{m}$  in the Anwar and Melles groups, respectively ( $P = 0.155$ ).

**Conclusions:** The Anwar and Melles techniques of DALK have comparable visual acuity and refractive outcomes, aberrometric profiles, biomechanical properties, corneal thicknesses, and endothelial cell densities. However, patients who underwent the Anwar technique showed better contrast sensitivity.

**Financial Disclosure(s):** The author(s) have no proprietary or commercial interest in any materials discussed in this article. *Ophthalmology* 2012;xx:xxx © 2012 by the American Academy of Ophthalmology.



Penetrating keratoplasty (PKP) has been the treatment of choice for advanced cases of keratoconus for a long time.<sup>1–3</sup> During the past decade, however, because of advancement in surgical techniques, deep anterior lamellar keratoplasty (DALK) has gained popularity in the treatment of keratoconus.<sup>4,5</sup> The advantages of DALK over PKP surgery include the following: immune rejection of the corneal endothelium cannot occur in DALK, DALK is extraocular and not intraocular, topical corticosteroids usually can be discontinued earlier with DALK, there is minor loss of endothelial cells with DALK, DALK may have superior resistance to rupture of the globe after blunt trauma, and sutures can be removed earlier after DALK.<sup>6,7</sup> With the advent of newer techniques and instrumentations, visual and refractive outcomes after DALK have been reported to be comparable with those after PKP.<sup>5,8–10</sup>

Different techniques for DALK have been introduced<sup>3</sup>; of them, the Anwar (or big-bubble) and Melles techniques are the 2 most popular. Two studies have compared the outcomes of these techniques for the treatment of keratoconus.<sup>11,12</sup> To the best of our knowledge, there is no randomized clinical trial comparing the outcome of these 2 techniques. The purpose of this study was to compare different features of Anwar versus Melles techniques in patients with advanced keratoconus.

### Patients and Methods

This prospective, randomized, double-blind clinical trial was conducted at Labafinejad Medical Center from June 2009 through October 2011. The study protocol was based on the tenets of the Declaration of Helsinki. It was approved by the institutional re-

view board and ethics committee of the Ophthalmic Research Center, Shahid Beheshti University of Medical Sciences. All possible risks and benefits were explained clearly to the patients before enrollment, and informed consent was obtained from all of them. The protocol of this trial has been registered and is available publicly at [clinicaltrials.gov](http://clinicaltrials.gov) (identifier number NCT00850148).

## Participants

Fifty-seven eyes of 57 patients 20 to 35 years of age with a clinical diagnosis of keratoconus who were contact lens intolerant and whose corrected distance visual acuity (CDVA) was less than 20/80 were enrolled. Clinical diagnosis was based on history, typical slit-lamp biomicroscopic findings (Vogt's striae, corneal thinning, and protrusion), keratometry, refraction, and topographic pattern. All patients were fitted in multiple sessions with multiple rigid gas permeable lenses by an experienced contact lens fitter. The best-fitted contact lens was administered for the patients. Contact lens intolerance was defined as constant foreign body sensation and eye irritation that obliged the patient to remove the contact lens. Exclusion criteria were prior intraocular surgery, deep central corneal opacities, previous history of hydrops, complicated postoperative course (rejection episodes, corneal ulceration, cataract development, and raised intraocular pressure), history of glaucoma or ocular hypertension, pregnancy, any type of allergic ocular diseases, and systemic disorders.

## Intervention

A complete eye examination including visual acuity measurement, biomicroscopic examination, intraocular pressure measurement, and funduscopy was performed. Eligible eyes were allocated randomly into 2 groups: those undergoing the Anwar technique and those undergoing the Melles technique.

## Surgical Technique

All participants were operated by 1 surgeon (A.B.R.). All surgeries were performed under general anesthesia. The trephine (Hessburg-Barron vacuum trephine; Katena Products, Denville, NJ) diameter was 3 mm less than the vertical corneal diameter. A 0.25-mm oversize donor was used for a vitreous length of 16.0 mm or more, and a 0.50-mm oversize donor was used for a vitreous length of less than 16.0 mm.<sup>13</sup> All grafts were secured using 16 interrupted 10-0 nylon sutures. Suture removal was based on the amount of corneal astigmatism, guided by topographic pattern. All patients underwent elevation topography (Orbscan II; Bausch & Lomb, Rochester, NY) to obtain thorough topographic and pachymetric maps of the cornea.

## Anwar (Big-Bubble) Technique

The recipient cornea was trephined for approximately 60% to 80% of its thickness, considering the thinnest point of the cornea in the area of trephination. A 27- or 30-gauge, 60- to 75-degree bent needle attached to a 5-ml air-filled syringe was inserted bevel down deep into the corneal stroma and was advanced for 2 to 4 mm, aiming posteriorly toward Descemet's membrane in a paracentral position at an angle almost parallel to the cornea. Air then was injected forcefully into the deep stroma, reaching a plane and causing a separation of the Descemet's membrane from the overlying stroma up to 0.5 to 1 mm away from the trephination edge. A partial-thickness anterior keratectomy then was performed using a crescent knife. A 15-degree knife was used to make an incision in the most elevated anterior wall of the big bubble. Viscoelastic

then was injected in the collapsed space. A blunt spatula was introduced in the space to make sure that the cleavage plane was complete. The stromal layers were divided in 4 quadrants and were excised with blunt-tipped microscissors. Descemet's membrane and endothelium of the donor eye were stained with trypan blue to enable identification and then were removed with a dry swab or forceps. After removal, the full-thickness corneal donor button was trephined with a Hessburg-Barron trephine and was sutured into the bed (Video 1, available at <http://aojournal.org>).

## Melles Technique

A self-sealing side-port incision was made at the limbus to release aqueous and to fill the anterior chamber with air. This created an optical air-endothelium interface, which acted as a convex mirror, reflecting back the depth of an instrument in the deep stroma. Afterward, the conjunctiva was opened at the 12-o'clock position and a scleral incision 5-mm long and 350- $\mu$ m deep was made 1 mm posterior to the limbus using a micrometer diamond knife. A Melles dissector was used for corneal separation up to the corneal periphery. A black band was visualized in front of the dissecting instrument, which represented twice the residual posterior stromal thickness. The correct depth was obtained when the black band disappeared and wrinkles became apparent in Descemet's membrane. The scleral incision was fixed with 2 10-0 nylon sutures. The air then was exchanged for balanced salt solution, viscoelastic was injected into the interface, and a Hessburg-Barron suction trephine was centered over the cornea and the blade was turned down until the anterior corneal lamella was perforated. The remaining tissue was removed using keratoplasty scissors, and the recipient bed was irrigated to remove overlying viscoelastic. Removal of Descemet's membrane and endothelium as well as keratoplasty were performed as indicated above (Video 2, available at <http://aojournal.org>).

## Postoperative Management

Patients received topical chloramphenicol 0.5% and dexamethasone 0.1% eye drops. The antibiotic was discontinued after complete epithelialization, whereas the steroid was tapered over the following 2 to 3 months. Patients were examined on postoperative days 1, 3, 7, 14, and 28; then biweekly until 3 months; then monthly until 1 year; and quarterly thereafter. All sutures were removed up to 12 months after surgery. At month 15 (3 months after final suture removal; primary end point), refraction, contrast sensitivity function (Mono ELC contrast sensitivity vision monitor system; Metrovision CS, P renchies, France), aberrometric profile (Zywave; Bausch & Lomb, Rochester, NY), endothelial cell count (Confoscan 3.4; Nidek Technology, Padova, Italy), central corneal thickness (ultrasonic pachymeter, Nidek UP 1000; Nidek Co., Gamagori, Japan), and corneal biomechanical properties (Ocular Response Analyzer; Reichert Ophthalmic Instruments, Buffalo, NY) were compared. All clinical examinations were carried out by one of the authors (M.M.S.), who was masked by the type of surgery.

## Outcome Measures

The primary outcome measure was CDVA. Secondary outcomes were spherical equivalent, contrast sensitivity, corneal aberrations, corneal biomechanical properties, endothelial cell count, and central corneal thickness.

## Contrast Sensitivity Testing

Contrast sensitivity was assessed using a Mono ELC contrast sensitivity vision monitoring system with best spectacle correction

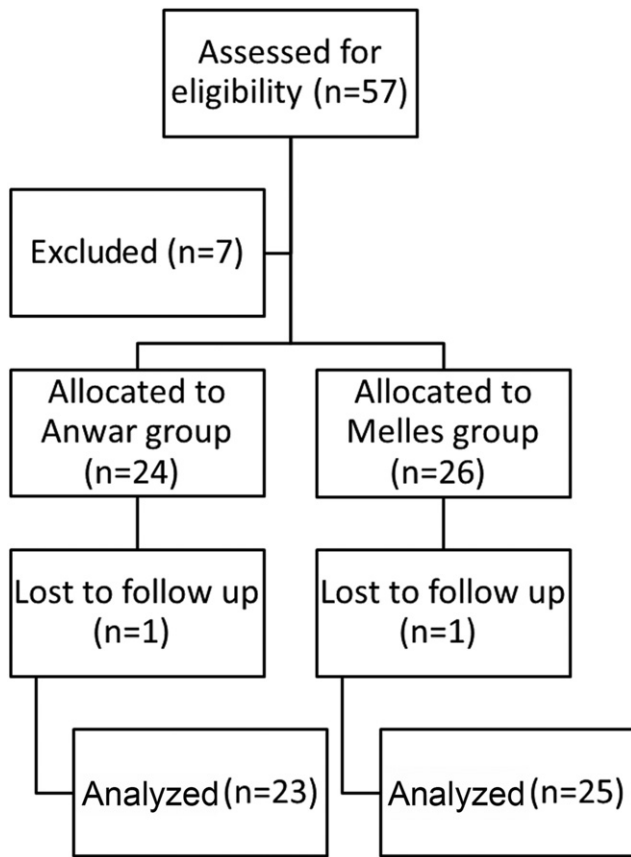


Figure 1. Flow diagram showing progression of subjects through the trial.

in place. The monitor system was positioned 3.5 m from the subject. The examination room had a luminance of 85 cd/mm<sup>2</sup> in photopic conditions and 5 cd/mm<sup>2</sup> in mesopic conditions. The test was performed using vertical sinusoidal gratings. Contrast thresholds were measured with an ascending limit technique for 5 spatial frequencies (0.8, 1.6, 3.2, 6.4, 12.8, and 25.6 cycles/degree) under photopic and mesopic illuminations. The results were presented in units of decibels (contrast [dB] =  $-10 \times \log \text{contrast}$ ).

### Wavefront Aberration Measurement

The corneal wavefront aberrations were measured in natural scotopic conditions after 5 minutes of dark adaptation. The second- to fourth-order aberrations were analyzed. The wavefront aberrations were presented as root mean square values. Three measurements were obtained from each eye after adjustment of the machine for

refractive errors. The average of the 3 values was used for statistical analysis. For each pair of standard Zernike terms including trefoil and coma, 1 value for the magnitude was calculated by Zernike analysis. Data were analyzed quantitatively in the central 5-mm diameter by expanding the set of Zernike polynomials.

### Sample Size

To have a 95% power for detection of a difference of 2 logarithm of the minimal angle of resolution (logMAR) (equal to 2 Snellen lines) in the mean visual acuity among the groups as significant (at the 2-sided 5% level) with an assumed standard deviation of 0.16 and considering 30% loss to follow-up, 25 eyes for each group were required.

### Randomization and Masking

Randomization was performed using the random block permutation method according to a computer-generated randomization list. The block length varied randomly (4 to 8). The random allocation sequence was performed by a biostatistician. The details of the series were unknown to the study investigators. Patients were masked to the type of surgery. Only 1 eye from each patient was included. If both eyes of 1 patient were eligible, the right eye of patient was included. The surgeon was informed about the type of surgery in the operating room. All paraclinical examinations were performed by experienced technicians who were masked to the type of surgery.

### Statistical Methods

Statistical analysis was performed using SPSS software version 17 (SPSS, Inc., Chicago, IL). To compare the data at baseline, the chi-square test or Fisher exact test was used for qualitative data and the *t* test was used for quantitative data. To compare the results between groups, the independent *t* test or Mann-Whitney *U* test was used based on normality tests results. A mixed model was used to compare and contrast sensitivity function results in different frequencies between the 2 groups.

### Results

Fifty-seven eyes of 57 patients underwent surgery. Of these, 7 eyes were excluded because of intraoperative or postoperative complications (see "Complications"). Two patients did not complete the follow-up period and were excluded from the analysis. Finally, 48 eyes from 48 patients (37 men and 11 women; 23 eyes in the Anwar group and 25 eyes in the Melles group) were analyzed (Fig 1). All patients were matched in terms of all baseline characteristics (Table 1).

Table 1. Preoperative Data of the Patients

Parameter	Total	Anwar Group	Melles Group	P Value
Age (yrs)	27.4±7.2 (15–42)	27.4±7.5 (15–42)	27.4±7.1 (17–41)	>0.99
CDVA (logMAR)	1.21±0.44 (0.18–2.1)	1.27±0.44 (0.18–2.1)	1.16±0.45 (0.18–1.9)	0.394
Spherical equivalent (diopters)	−5.99±2.54 (−12.63 to 1)	−6.02±2.88 (−12.63 to 1)	−5.95±2.15 (−11.5 to −3)	0.925
Keratometry (diopters)	56.3±7.1 (40.2–81.9)	57.6±7.1 (50.5–81.9)	55.2±5.9 (40.2–65)	0.142
Endothelial cell density (cells/mm <sup>2</sup> )	2896±448 (2019–3547)	2953±432 (2019–3547)	2839±465 (2089–3456)	0.372

CDVA = corrected distance visual acuity; logMAR = logarithm of the minimum angle of resolution. All data are presented as mean±standard deviation (range), unless otherwise indicated.

Table 2. Photopic Contrast Sensitivity Function in Different Spatial Frequencies 15 Months after Surgery

Spatial Frequency (CPD)	Total		Anwar Group		Melles Group		P Value
	Mean±SD	Median (Range)	Mean±SD	Median (Range)	Mean±SD	Median (Range)	
0.8	2.8±0.1	2.9 (2.6–2.9)	2.9±0.1	2.9 (2.8–2.9)	2.8±0.1	2.8 (2.6–2.9)	0.004
1.6	2.9±0.2	2.9 (2.4–3.1)	3±0.2	3 (2.4–3.1)	2.8±0.2	2.8 (2.5–3.1)	0.006
3.2	2.9±0.2	2.9 (2.2–3.3)	3±0.2	2.9 (2.3–3.3)	2.8±0.2	2.8 (2.2–3.3)	0.005
6.4	2.6±0.3	2.6 (1.8–3.2)	2.7±0.3	2.7 (1.9–3.2)	2.5±0.3	2.6 (1.8–3.2)	0.061
12.8	2.1±0.6	2.3 (1.1–3)	2.2±0.6	2.4 (1.1–3)	2±0.5	2.2 (1.1–3)	0.306
25.6	1.5±0.5	1.4 (0.7–2.6)	1.6±0.5	1.4 (1.1–2.6)	1.3±0.4	1.4 (0.7–2.6)	0.048

CPD = cycles per degree; SD = standard deviation.

## Visual and Refractive Outcomes

Fifteen months after surgery, the mean CDVA was  $0.17 \pm 0.09$  logMAR (range, 0–0.3 logMAR) in the Anwar group and  $0.18 \pm 0.11$  logMAR (range, 0–0.4 logMAR) in the Melles group (95% confidence interval [CI],  $-0.07$  to  $0.05$ ;  $P = 0.803$ ). The mean spherical equivalent was  $-1.82 \pm 2.7$  diopters (D; range,  $-11$  to  $3.25$  D) and  $-2.69 \pm 3.94$  D (range,  $-10.75$  to  $3.63$  D) in the Anwar and Melles groups, respectively (95% CI,  $-1.06$  to  $2.8$ ;  $P = 0.155$ ). Keratometric astigmatism was not significantly different between 2 groups. The mean was  $3.16 \pm 1.82$  D (range,  $0.5$ – $7.5$  D) and  $3.24 \pm 2.53$  D (range,  $0$ – $10$  D) in the Anwar and Melles groups, respectively (95% CI,  $-1.34$  to  $1.19$ ;  $P = 0.384$ ).

## Contrast Sensitivity

Photopic and mesopic contrast sensitivity functions of eyes in both groups 15 months after surgery are shown in Tables 2 and 3, respectively. The overall difference in photopic contrast sensitivity function between the 2 groups was statistically significant ( $P = 0.023$ ; Fig 2). In addition, there was a significant overall difference in mesopic contrast sensitivity function between the 2 groups ( $P = 0.030$ ; Fig 3).

## Corneal Wavefront Aberrometry

Corneal wavefront aberration measurements are shown in Figure 4. There was no significant difference between the 2 groups in total and higher-order aberrations up to the fifth order (Table 4).

## Biomechanical Properties

Corneal biomechanical properties were the same in the 2 groups. Corneal hysteresis was not significantly different between the

Anwar and Melles groups, respectively (mean,  $9.85 \pm 0.79$  [range,  $8.6$ – $11.3$ ] vs. mean,  $9.89 \pm 0.64$  [range,  $8.8$ – $11.4$ ]; 95% CI,  $-0.45$  to  $0.36$ ;  $P = 0.83$ ). The mean corneal resistance factor was  $10.02 \pm 0.8$  (range,  $8.6$ – $11.7$ ) and  $10.13 \pm 0.76$  (range,  $9$ – $11.7$ ) in the Anwar and Melles groups, respectively, 15 months after surgery (95% CI,  $-0.55$  to  $0.33$ ;  $P = 0.62$ ).

## Endothelial Cell Density and Corneal Thickness

Fifteen months after surgery, the mean endothelial cell density was  $2939 \pm 435$  cell/mm<sup>2</sup> (range,  $2020$ – $3503$  cell/mm<sup>2</sup>) and  $2808 \pm 435$  cell/mm<sup>2</sup> (range,  $2130$ – $3414$  cell/mm<sup>2</sup>) in the Anwar and Melles groups, respectively ( $P = 0.41$ ). There was no significant difference in percentage of endothelial cell loss between the 2 groups ( $1 \pm 2\%$  vs.  $1 \pm 3\%$  in the Anwar and Melles groups, respectively;  $P = 0.869$ ). Mean central corneal thickness was  $525.56 \pm 47.87$   $\mu$ m (range,  $442$ – $668$   $\mu$ m) versus  $504.64 \pm 54.20$   $\mu$ m (range,  $368$ – $593$   $\mu$ m) in the Anwar and Melles groups, respectively ( $P = 0.155$ ).

## Complications

In 1 case, Descemet's membrane was not bared during the Anwar procedure. Descemet rupture occurred in 3 cases during surgery (2 cases in the Anwar group and 1 case in the Melles group). Two subepithelial rejections in the Melles group and 1 epithelial rejection in the Anwar group occurred. All these cases were excluded from the study.

## Discussion

This study showed that the Anwar and Melles techniques of DALK are effective for visual rehabilitation in eyes with

Table 3. Mesopic Contrast Sensitivity Function in Different Spatial Frequencies 15 Months after Surgery

Frequency (CPD)	Total		Anwar Group		Melles Group		P Value
	Mean±SD	Median (Range)	Mean±SD	Median (Range)	Mean±SD	Median (Range)	
0.8	2.8±0.1	2.9 (2.6–2.9)	2.9±0.1	2.9 (2.8–2.9)	2.8±0.1	2.8 (2.6–2.9)	0.004
1.6	2.9±0.2	2.9 (2.4–3.1)	3±0.2	3 (2.4–3.1)	2.8±0.2	2.8 (2.5–3.1)	0.006
3.2	2.9±0.2	2.9 (2.2–3.3)	3±0.2	2.9 (2.3–3.3)	2.8±0.2	2.8 (2.2–3.3)	0.005
6.4	2.6±0.3	2.6 (1.8–3.2)	2.7±0.3	2.7 (1.9–3.2)	2.5±0.3	2.6 (1.8–3.2)	0.061
12.8	2.1±0.6	2.3 (1.1–3)	2.2±0.6	2.4 (1.1–3)	2±0.5	2.2 (1.1–3)	0.306
25.6	1.5±0.5	1.4 (0.7–2.6)	1.6±0.5	1.4 (1.1–2.6)	1.3±0.4	1.4 (0.7–2.6)	0.048

CPD = cycle per degree; SD = standard deviation.



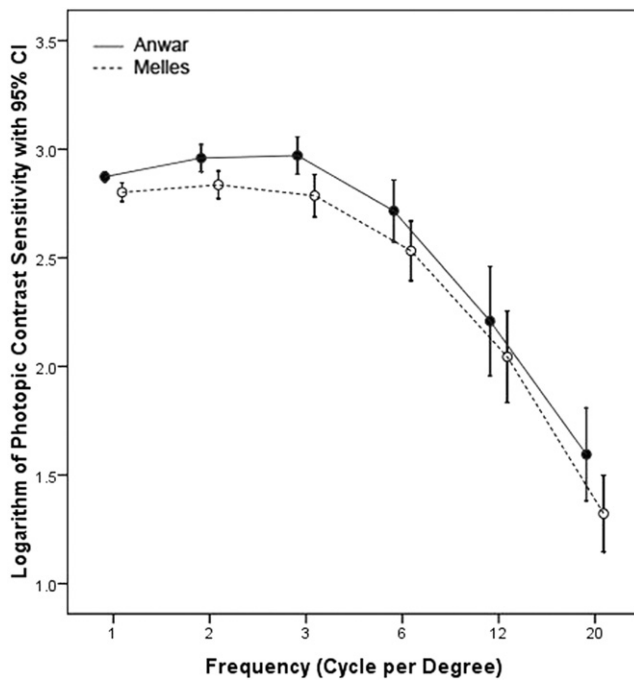


Figure 2. Graph showing photopic contrast sensitivity with 95% confidence interval (CI) in different spatial frequencies in the 2 groups. Note the overall better contrast sensitivity in the Anwar group.

advanced keratoconus. They have comparable visual acuity and refractive outcomes, aberrometric profiles, biomechanical properties, corneal thicknesses, and endothelial cell densities. However, patients who underwent the Anwar technique showed better visual quality in terms of contrast sensitivity.

In this study, visual acuity and refractive results were the same between the 2 groups after surgery. It has been shown that postoperative CDVA is the same after surgery between these 2 techniques.<sup>12</sup> Moreover, it has been shown that there is no difference in visual acuity between pre-Descemet and Descemet DALK.<sup>14</sup> In contrast, in another study, the Anwar and Melles groups showed a significant difference in CDVA after 12 months (0.15 logMAR vs. 0.41 logMAR).<sup>11</sup> It has been shown that visual acuity is related to the residual recipient corneal stromal thickness.<sup>6</sup> In one study, eyes with a recipient corneal stromal bed thickness of less than 20  $\mu\text{m}$  had visual acuities similar to those of eyes that had undergone PKP, whereas those with a recipient thickness of more than 80  $\mu\text{m}$  had a significantly reduced visual acuity.<sup>15</sup> However, total corneal thickness had no significant effect on the postoperative visual acuity.<sup>15</sup> Thus, based on the present results, the remaining stromal thickness in the Melles group was minimal and could not have affected the visual outcome.

We did not find any significant differences between the aberrometric profiles of the 2 groups. This suggests that graft interface in DALK does not induce significant additional aberrations that can disturb visual function. There is no study comparing the aberrometric profile of different DALK procedures. However, in several studies comparing aberrations between DALK and PKP, no significant differ-

ences in total and ocular higher-order aberrations were reported.<sup>15–18</sup> In contrast, in another study, ocular higher-order aberrations were more common in DALK than in PKP.<sup>19</sup>

Photopic and mesopic contrast sensitivities were better in the Anwar group than in the Melles group. In one study, the quality of vision after DALK was comparable with that after PKP when stromal excision was extended to the Descemet's membrane and was inferior to PKP when layers of stroma were left adherent to the Descemet's membrane.<sup>16</sup> In another study, although not statistically significant, a reduction in photopic contrast sensitivity was noted after DALK with a recipient stromal thickness of more than 80  $\mu\text{m}$ .<sup>15</sup>

The main distinguishing feature of different DALK techniques is remaining stromal bed thickness.<sup>4,6</sup> It has been shown that the visual function after DALK is dependent on the remaining stromal bed thickness; the less remaining stromal bed thickness, the better visual function is.<sup>6,11,12,15,16,20</sup> If a significant amount of pre-Descemet's stroma is left in the recipient bed, then visual acuity can be affected.<sup>6,11,15,16,21</sup> However, the high quality of this interface has been reported to be responsible for good visual results comparable with those of PKP. Visual acuity can be impeded by optical interference, which can be independent of clinically visible interface haze. If Descemet's membrane is exposed in the visual axis and there are no Descemet's membrane folds or remaining stromal bed in the visual axis, then visual acuity is similar for DALK and PKP. In the present study, postoperative central pachymetry was similar in the 2 groups, suggesting that stromal dissection in the Melles group was conducted at a deep stromal level, very close to the Descemet's membrane. Therefore, despite sim-

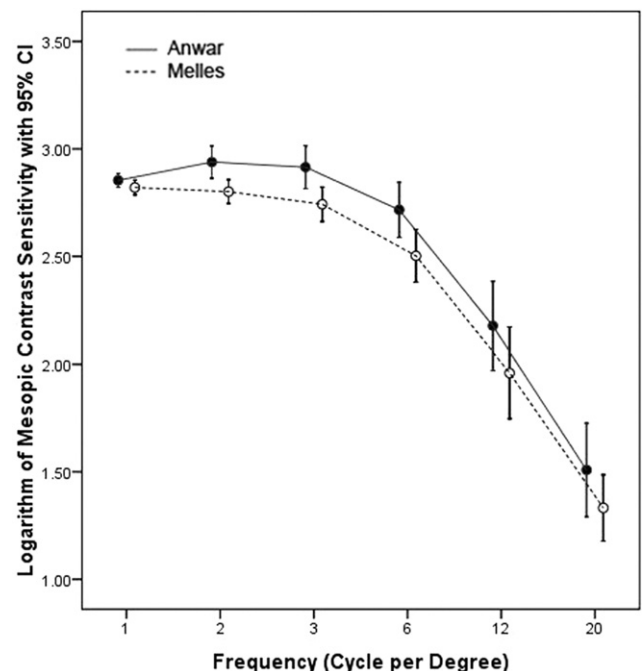


Figure 3. Graph showing mesopic contrast sensitivity with 95% confidence interval (CI) in different spatial frequencies in 2 groups. Note the overall better contrast sensitivity in the Anwar group.

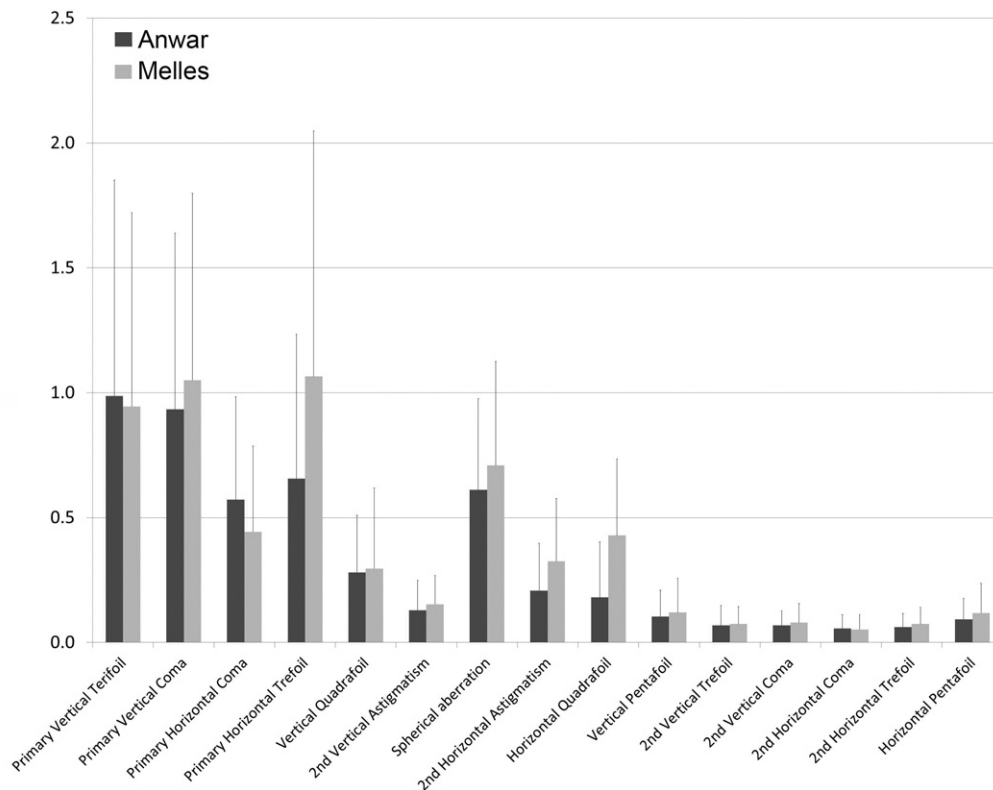


Figure 4. Bar graph showing the aberrometric profile of the 2 techniques of deep anterior lamellar keratoplasty in patients with keratoconus.

ilar central corneal thicknesses and a tiny amount of remaining stromal bed with similar visual acuities, refractive results, and aberrometric profiles, contrast sensitivity can be affected by interface irregularity (Fig 5). In vivo confocal microscopy and scanning electron microscopy studies have demonstrated that the interface achieved with the Anwar technique is clean, regular, hyporeflective, and devoid of cells.<sup>22</sup>

Endothelial cell loss was similar between the 2 groups in this study. This shows that these 2 surgeries are safe and affect the endothelial cells in a similar manner. The 2 groups had the same corneal hysteresis and corneal resistance factor 15 months after DALK. This shows that the type of DALK

technique does not affect the corneal biomechanical properties. Moreover, it has been shown that DALK preserves the biomechanical strength of the corneas to normal values.<sup>23</sup>

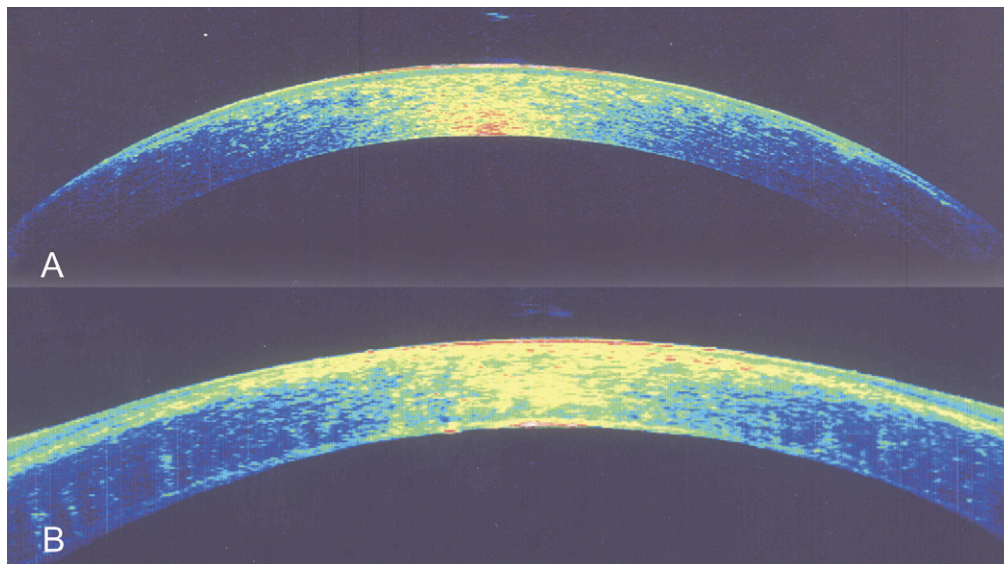
Imprecise judgment of corneal depth in the Melles technique prevents baring of Descemet's membrane. Despite lower contrast sensitivity after the Melles technique, it has some specific indications. In keratoconic eyes that have had previous hydrops, traumatic penetrating injuries to the central cornea, or severe microbial infections with residual scarring down to Descemet's membrane, the Anwar technique usually is not successful.<sup>6</sup> The Melles technique can be considered in these cases, although final vision may not be as good as that after PKP.

Table 4. Aberrometric Data 15 Months after Surgery

Parameter	Anwar Group	Melles Group	P Value
Irregularity 3 mm	3.45±1.52 (1.5–6.9)	3.13±1.13 (1.5–6.9)	0.699
Irregularity 5 mm	6.04±1.93 (3.6–9.6)	5.39±1.27 (3.7–9.6)	0.326
Total RMS	6.71±3.59 (1.64–13.86)	7.79±4.54 (1.59–16.03)	0.541
HOA RMS	2.16±0.99 (0.94–5.01)	2.42±0.92 (1.29–4.92)	0.276
Third-order RMS	1.89±0.86 (0.44–4.74)	2.15±0.95 (0.98–4.84)	0.438
Trefoil RMS	1.34±0.83 (0.11–3.89)	1.61±1 (0.4–4.83)	0.322
Coma RMS	1.2±0.66 (0.4–2.71)	1.23±0.69 (0.08–2.7)	0.831
Fourth-order RMS	1.03±0.37 (0.31–1.61)	1.11±0.33 (0.58–2.19)	0.173
Spherical aberration RMS	0.61±0.36 (0.05–1.24)	0.71±0.42 (0.12–2.07)	0.727
Fifth-order RMS	0.22±0.14 (0–0.6)	0.26±0.18 (0–0.58)	0.351

HOA = higher-order aberrations; RMS = root mean square.

All data are presented as mean±standard deviation (range), unless otherwise indicated.



**Figure 5.** Corneal optical coherence tomography images of patients after undergoing the (A) Anwar and (B) Melles techniques. Note the tiny remaining stromal bed and its mild irregularity in Melles deep anterior lamellar keratoplasty.

Several studies have evaluated the outcomes of DALK; however, they are different in terms of outcome measures, study design, methods of visual function testing, surgical techniques, surgeons' preferences, sample size, and surgical indications.<sup>6,8–11,14–21,24,25</sup> In the present study, patients with a single diagnosis of keratoconus who randomly underwent DALK (using the Anwar or Melles technique) were selected and operated on by 1 surgeon in a similar manner. The same inclusion criteria were applied to both groups. Cases with complicated intraoperative or postoperative courses were excluded to avoid confounding factors that might have affected treatment results. Moreover, this study was a randomized, double-blind clinical trial. The sample size was calculated based on visual acuity. This may limit the reliability of the evaluation of other parameters that were not found to be significant in the 2 groups. However, post hoc sample size estimation for nonsignificant results showed adequate enrollment for secondary outcome measures.

In conclusion, both the Anwar and Melles techniques of DALK for keratoconus have comparable visual, refractive, aberrometric profile, and biomechanical outcomes, except for contrast sensitivity, which is better with the Anwar technique.<sup>13</sup>

## References

- Ghosheh FR, Cremona FA, Rapuano CJ, et al. Trends in penetrating keratoplasty in the United States 1980–2005. *Int Ophthalmol* 2008;28:147–53.
- Jhanji V, Sharma N, Vajpayee RB. Management of keratoconus: current scenario. *Br J Ophthalmol* 2011;95:1044–50.
- Luengo-Gimeno F, Tan DT, Mehta JS. Evolution of deep anterior lamellar keratoplasty (DALK). *Ocul Surf* 2011;9:98–110.
- Shimmura S, Tsubota K. Deep anterior lamellar keratoplasty. *Curr Opin Ophthalmol* 2006;17:349–55.
- Tan DT, Por YM. Current treatment options for corneal ectasia. *Curr Opin Ophthalmol* 2007;18:284–9.
- Reinhart WJ, Musch DC, Jacobs DS, et al. Deep anterior lamellar keratoplasty as an alternative to penetrating keratoplasty: a report by the American Academy of Ophthalmology. *Ophthalmology* 2011;118:209–18.
- Borderie VM, Sandali O, Bullet J, et al. Long-term results of deep anterior lamellar versus penetrating keratoplasty. *Ophthalmology* 2012;119:249–55.
- Funnell CL, Ball J, Noble BA. Comparative cohort study of the outcomes of deep lamellar keratoplasty and penetrating keratoplasty for keratoconus. *Eye (Lond)* 2006;20:527–32.
- Shimazaki J, Shimmura S, Ishioka M, Tsubota K. Randomized clinical trial of deep lamellar keratoplasty vs penetrating keratoplasty. *Am J Ophthalmol* 2002;134:159–65.
- Watson SL, Ramsay A, Dart JK, et al. Comparison of deep lamellar keratoplasty and penetrating keratoplasty in patients with keratoconus. *Ophthalmology* 2004;111:1676–82.
- Han DC, Mehta JS, Por YM, et al. Comparison of outcomes of lamellar keratoplasty and penetrating keratoplasty in keratoconus. *Am J Ophthalmol* 2009;148:744–51.
- Sarnicola V, Toro P, Gentile D, Hannush SB. Descemet DALK and predescemet DALK: outcomes in 236 cases of keratoconus. *Cornea* 2011;29:53–9.
- Javadi MA, Feizi S, Rastegarpour A. Effect of vitreous length and trephine size disparity on post-DALK refractive status. *Cornea* 2011;30:419–23.
- Feizi S, Javadi MA, Jamali H, Mirbabaee F. Deep anterior lamellar keratoplasty in patients with keratoconus: big-bubble technique. *Cornea* 2011;29:177–82.
- Ardjomand N, Hau S, McAlister JC, et al. Quality of vision and graft thickness in deep anterior lamellar and penetrating corneal allografts. *Am J Ophthalmol* 2007;143:228–35.
- Fontana L, Parente G, Sincich A, Tassinari G. Influence of graft-host interface on the quality of vision after deep anterior lamellar keratoplasty in patients with keratoconus. *Cornea* 2011;30:497–502.
- Koh S, Maeda N, Nakagawa T, et al. Characteristic higher-order aberrations of the anterior and posterior corneal surfaces



- in 3 corneal transplantation techniques. *Am J Ophthalmol* 2012;153:284–90.
18. Javadi MA, Feizi S, Yazdani S, Mirbabaee F. Deep anterior lamellar keratoplasty versus penetrating keratoplasty for keratoconus: a clinical trial. *Cornea* 2011;29:365–71.
  19. Bahar I, Kaiserman I, Srinivasan S, et al. Comparison of three different techniques of corneal transplantation for keratoconus. *Am J Ophthalmol* 2008;146:905–12.
  20. Feizi S, Javadi MA, Rastegarpour A. Visual acuity and refraction after deep anterior lamellar keratoplasty with and without successful big-bubble formation. *Cornea* 2011;29:1252–5.
  21. Alio JL. Visual improvement after late debridement of residual stroma after anterior lamellar keratoplasty. *Cornea* 2008;27:871–3.
  22. Feizi S, Javadi MA, Kanavi MR. Cellular changes of donor corneal tissue after deep anterior lamellar keratoplasty versus penetrating keratoplasty in eyes with keratoconus: a confocal study. *Cornea* 2011;29:866–70.
  23. Hosny M, Hassaballa MA, Shalaby A. Changes in corneal biomechanics following different keratoplasty techniques. *Clin Ophthalmol* 2011;5:767–70.
  24. Borderie VM, Werthel AL, Touzeau O, et al. Comparison of techniques used for removing the recipient stroma in anterior lamellar keratoplasty. *Arch Ophthalmol* 2008;126:31–7.
  25. Panda A, Bageshwar LM, Ray M, et al. Deep lamellar keratoplasty versus penetrating keratoplasty for corneal lesions. *Cornea* 1999;18:172–5.

## Footnotes and Financial Disclosures

Originally received: January 22, 2012.

Final revision: July 30, 2012.

Accepted: July 31, 2012.

Available online: ●●●

Manuscript no. 2012-93.

<sup>1</sup> Ophthalmic Research Center, Labbafinejad Medical Center, Shahid Beheshti University of Medical Sciences, Tehran, Iran.

<sup>2</sup> School of Medicine, Tehran University of Medical Sciences, Tehran, Iran.

### Financial Disclosure(s):

The author(s) have no proprietary or commercial interest in any materials discussed in this article.

Supported by a grant from Ophthalmic Research Center, Shahid Beheshti University of Medical Sciences, Tehran, Iran, which had no role in the design or conduct of this research.

### Correspondence:

Medi Eslani, MD, Labbafinejad Medical Center, Boostan 9 Street, Pasdaran Avenue, Tehran 16666, Iran. E-mail: dr.eslani@gmail.com.