



Disponible en ligne sur

ScienceDirect
www.sciencedirect.com

Elsevier Masson France

EM|consulte
www.em-consulte.com

**Annales
d'Endocrinologie**
Annals of Endocrinology

Annales d'Endocrinologie xxx (2015) xxx–xxx

Consensus

Neuro-ophthalmologic exploration in non-functioning pituitary adenoma[☆]

Explorations neuro-ophthalmologiques d'un adénome hypophysaire non fonctionnel

Lucie Abouaf^{a,b,*}, Alain Vighetto^{a,b}, Maud Lebas^c

^a Unité de neuro-ophthalmologie, service de neurologie D, hôpital neurologique, hospices civils de Lyon, groupement hospitalier Est, 59, boulevard Pinel, 69500 Bron, France

^b Université Claude-Bernard Lyon-1, 43, boulevard du 11-Novembre-1918, 69622 Villeurbanne cedex, France

^c Clinique Mathilde, 4, rue Lessard, 76100 Rouen, France

Abstract

Non-functioning pituitary adenoma may lead to blindness and causes visual impairment in 58% of cases and, more rarely, ocular motor disorder. Patients are slow to become aware of their visual dysfunction, vision in one eye compensating the deficit in the other. Assessment of visual function, comprising visual acuity and visual field evaluation and fundus examination, should be performed regularly according to the severity of impairment. Optic nerve optical coherence tomography (OCT) can quantify optic atrophy reproducibly, and is of prognostic value for postoperative visual recovery. Diplopia most often involves decompensation of heterophoria, visual field fusion being hampered by the visual field defect; such diplopia without ocular motor deficit is known as "hemifield slide". Diplopia associated with ocular motor palsy is caused by tumoral invasion of the cavernous sinus (IIIrd, IVth or VIth nerve palsy); in large impairment, restricted eye movement is easily observed; milder palsies require neuro-ophthalmologic assessment and/or Lancaster test. Pituitary apoplexy induces ocular motor impairment in 70% of cases, strongly guiding diagnosis. Visual impairment is associated in 75% of cases. The degree of neuro-ophthalmologic (visual and ocular motor) impairment is one of the main criteria guiding treatment of pituitary apoplexy (conservative medical and/or surgical treatment) and follow-up.

© 2015 Published by Elsevier Masson SAS.

Keywords: Pituitary adenoma; Non-functioning pituitary adenoma; Visual field defect; Diplopia

Résumé

Les adénomes hypophysaires non fonctionnels, pathologie potentiellement cécitante, sont responsables d'atteinte visuelle dans 58 % des cas et plus rarement de troubles oculomoteurs. L'atteinte de la fonction visuelle est longtemps asymptomatique, par compensation de l'œil controlatéral. Il est nécessaire d'effectuer une évaluation de l'acuité visuelle, du champ visuel et du fond d'œil de manière régulière, la fréquence dépendant de la sévérité de l'atteinte (entre tous les 3 à 6 mois au début). L'*optical coherence tomography* (OCT) du nerf optique peut compléter le bilan, et comporte une valeur reproductible, de suivi et pronostique, sur la récupération post-opératoire. Les diplopies les plus fréquentes sont en général liées à la décompensation de phories par le déficit du champ visuel, avec une perte de la capacité fusionnelle, sans déficit oculomoteur, et portent le nom de « glissement de l'hémichamp ». En cas de paralysie oculomotrice, l'atteinte est liée à l'envahissement du sinus caverneux par la tumeur (paralysie du III, du IV, ou du VI). Lorsque le déficit est important, une limitation des mouvements de l'œil est facilement observée. Lorsqu'il est minime, il nécessite un bilan orthoptique et/ou un test de Lancaster. En cas d'apoplexie pituitaire, l'atteinte oculomotrice, qui est présente dans

DOIs of original articles: <http://dx.doi.org/10.1016/j.ando.2015.04.004>, <http://dx.doi.org/10.1016/j.ando.2015.04.002>, <http://dx.doi.org/10.1016/j.ando.2015.04.005>, <http://dx.doi.org/10.1016/j.ando.2015.04.007>, <http://dx.doi.org/10.1016/j.ando.2015.04.003>

[☆] Consensus of the French Endocrine Society: non-functioning pituitary adenoma.

* Corresponding author at: Unité de neuro-ophthalmologie, service de neurologie D, hôpital neurologique, hospices civils de Lyon, groupement hospitalier Est, 59, boulevard Pinel, 69500 Bron, France.

E-mail address: lucie.abouaf@chu-lyon.fr (L. Abouaf).

<http://dx.doi.org/10.1016/j.ando.2015.04.006>

0003-4266/© 2015 Published by Elsevier Masson SAS.

70 % des cas, prédomine et est fortement évocatrice. Une baisse visuelle associée est observée dans 75 % des cas d'apoplexie. L'importance de l'atteinte neuro-ophtalmologique (visuelle et oculomotrice) est un des éléments essentiels dans le choix du traitement (médical conservateur et/ou chirurgical), ainsi que dans le suivi de cette pathologie.

© 2015 Publié par Elsevier Masson SAS.

Mots clés : Adénome hypophysaire ; Adénome hypophysaire non fonctionnel ; Altération du champ visuel ; Diplopie

1. Introduction

Non-functioning pituitary adenoma (NFPA) is a major source of visual disorders, and is diagnosed later than functioning adenoma, often with larger tumor volume. Incidence of NFPA was 28–33.2% in pituitary adenoma populations, with or without visual involvement [1,2], but 58% in case of pituitary adenoma specifically with visual involvement [3]. Patients may be unaware of their deficit, especially in case of bitemporal hemianopsia, as functioning visual field in one eye can long compensate for visual field loss in the other.

Ocular motor impairment is mainly due to compression or invasion of the cavernous sinus, and is more frequent in case of large pituitary adenoma.

Finally, neuro-ophtalmologic involvement is critical in pituitary apoplexy, very frequently associating visual disorder, ocular motor disorder and headache of exceptionally sudden onset or with rapid progression.

The present paper will deal successively with visual involvement (acuity and visual field), ocular motor disorder, and neuro-ophtalmologic involvement in pituitary apoplexy.

2. Visual impairment

2.1. Anatomic bases

The visual impairment is caused by compression of the anterior visual pathways (optic nerves, chiasm, optic tracts) by the adenoma. The anatomic position of the anterior visual pathways with respect to the pituitary gland varies greatly from individual to individual, as does tumor orientation. Thus, while compression is usually chiasmal, it may also involve one or both optic nerves anteriorly or optic tract(s) posteriorly.

The ganglion-cell fibers that constitute the optic nerve change in spatial relation between the origin (in the inner retinal layers) and termination (in the lateral geniculate body).

Their organization in the retina and head of the optic nerve is as follows (Fig. 1): the fibers of the nasal retinal hemifield (temporal visual hemifield) are shown in blue and are distributed over the entire circumference of the optic nerve head when they reach it (blind-spot). The fibers of the temporal retinal hemifield (nasal visual hemifield) are shown in pink and are mainly located at the superior and inferior poles of the optic nerve head.

Along the optic nerve, the fibers gradually shift, bringing together those of a given quadrant of the visual field, with fibers corresponding to the superior and inferior temporal fields on the inside, ready to decussate, and those corresponding to the superior and inferior nasal fields remaining on the outside (Fig. 2).

A simplified diagram of fiber distribution (Fig. 3) is enough to explain the visual disorders induced by pituitary adenoma. At the chiasm, the ganglion cell fibers corresponding to the temporal hemifield of either eye cross the midline into the contralateral optic tract, while those corresponding to the nasal hemifield enter the ipsilateral tract, without decussation. Thus, visual information corresponding to the right hemifield is entirely encoded in the left optic tract, and vice-versa. Fibers encoding the superior temporal hemifield, when they cross over, initially head for the contralateral optic nerve before joining the contralateral tract; damage to these fibers is the source of the junctional Traquair syndrome (junctional scotoma) (cf. “Initial assessment”, below).

2.2. Pathophysiology

Contact between a pituitary adenoma and the anterior visual pathways is not in itself of visual impact. It is compression that induces visual disorder; the compression, however, is not measurable and is only indirectly suspected on imaging, as displacement of the visual pathways in contact with the tumor is present.

Several mechanisms are implicated in onset of visual impairment; initially reversible, they become irreversible. Reversible functional mechanisms comprise axoplasmic flow disorder, conduction blockage and demyelination. Irreversible mechanisms consist in axonal fiber degeneration under longer and/or more intense compression. This is seen in the fundus as optic atrophy; the level of redundancy of ganglion cell fibers forming the optic nerve and encoding visual information, however, means that a small degree of atrophy may be without functional impact, leaving visual acuity and the visual field normal. Advanced optic atrophy, on the other hand, induces lasting deficit, even after compression has been relieved by surgery.

2.3. Initial assessment

Ophthalmologic assessment includes visual acuity, pupil and fundus examination, ocular motor assessment and examination for ptosis (including cover test ± Hess-Weiss coordimetric graph if necessary) and visual field assessment. The rest of the usual ophthalmologic assessment protocol (refraction, intra-ocular pressure, anterior segment slit-lamp examination, retinal examination) is also systematically performed, as other ophthalmic pathologies may interfere with the tumor-induced deficits: notably, severe myopia and tilted disc syndrome may mimic bitemporal visual field defect (Fig. 4A and B), and need to be identified.

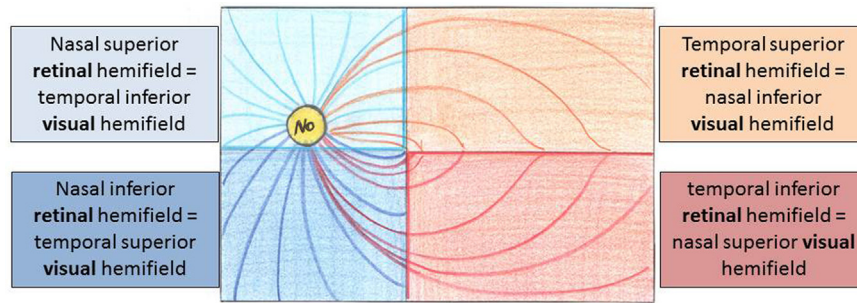


Fig. 1. Retinal organization of ganglion-cell fibers from retinal origin to optic nerve head (left eye, fundus view). ON: optic nerve.

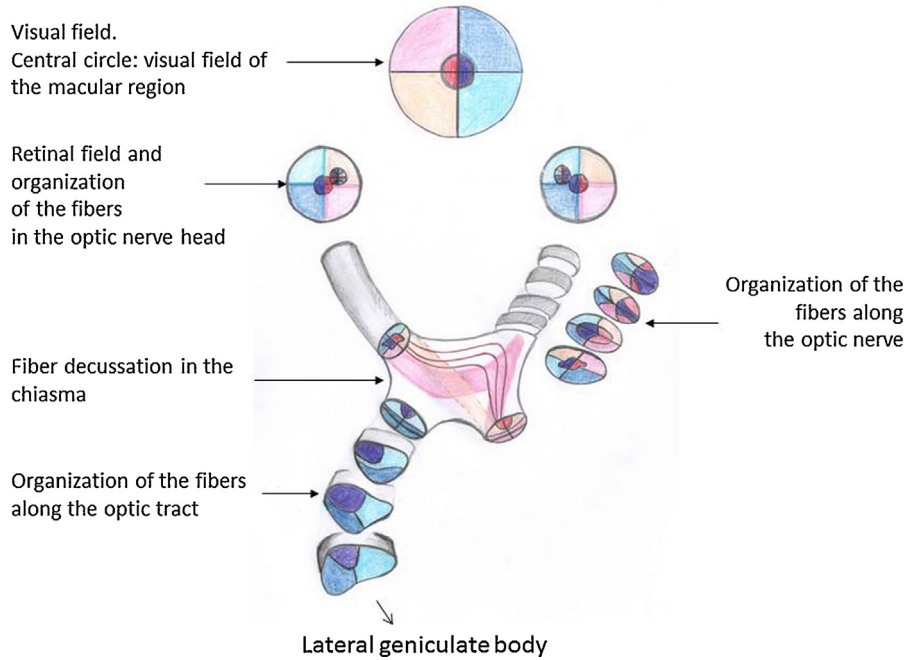


Fig. 2. Evolution of ganglion-cell fiber distribution along the anterior visual pathways according to visual field region encoded.

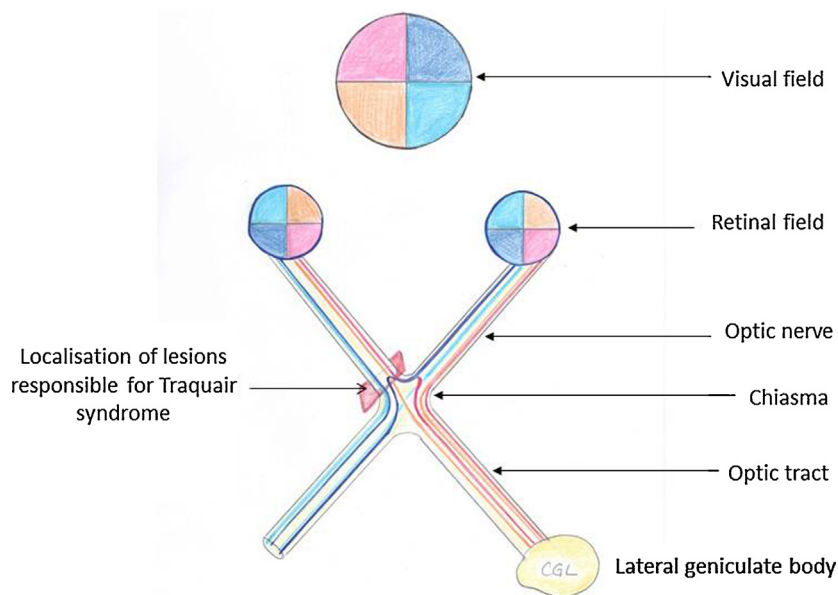


Fig. 3. Simplified diagram of the anterior visual pathways and chiasmal decussation. A bundle coding for the superior temporal field advances toward the contralateral optic nerve at decussation; this underlies the junctional Traquair syndrome (junctional scotoma).

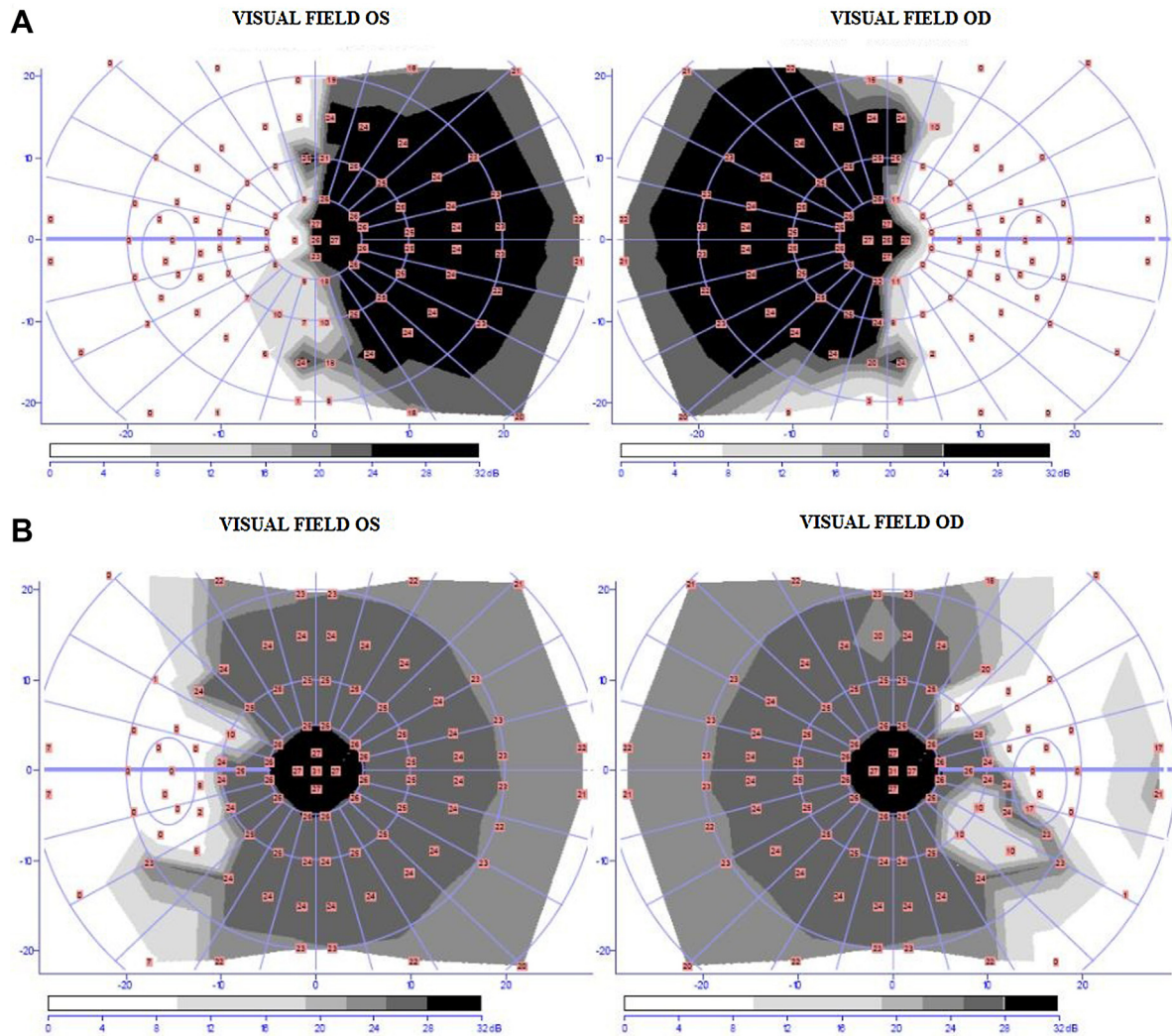


Fig. 4. A. Bitemporal hemianopia due to chiasmal compression by pituitary adenoma. Note that the deficit stops at the vertical meridian. B. False bitemporal hemianopia due to severe myopia. The defect limit seems vertical, but does not follow the vertical meridian, which passes through the center of vision.

2.3.1. Visual field assessment

The visual field assessment is classically an automatic visual field test, enabling quantified assessment of defect, test reliability and foveal threshold (i.e., macular region sensitivity) for comparison with visual acuity data. Although the test routinely assesses only the central 24–30°, it detects the vast majority of defects induced by pituitary adenoma. Several devices may be used (Humphrey, Octopus and Métrovision being the most common in France), providing comparable results. The Goldmann visual field test assesses the periphery up to 90° laterally; it is mainly used in case of severely impaired acuity or with non-compliant patients, and is also useful in suspected junctional scotoma (involving the optic nerve immediately next to the chiasm), comprising a defect of the visual field ipsilateral to the compressed nerve associated with superior temporal peripheral defect in the contralateral eye (Fig. 5), corresponding to a bundle of fibers from the eye contralateral to the lesion which, just before the chiasmatic cross-over, advance slightly within the optic nerve ipsilateral to the lesion. This clinical presentation has the interest of specifying location of the compressive lesion.

2.3.2. Optical coherence tomography (OCT) of the optic nerve head

Optical Coherence Tomography (OCT) of the optic nerve head is usually performed in case of visual impairment, for prognostic purposes. It is a non-invasive ocular imaging technique, without contact, based on infrared light (820 nm), enabling in-vivo assessment of eye tissue structure. The RNFL (retinal nerve fiber layer) module quantitatively estimates the number of ganglion cell axons constituting the optic nerve; this is a means of quantifying optic nerve atrophy, whereas the pale aspect of the nerve head in the fundus is subjective and non-quantifiable. Analysis provides a mean RNFL value and values per quadrant (temporal, nasal, superior and inferior). The prognostic value of this examination is discussed below.

2.4. Follow-up

If the tumor is in contact with the anterior visual pathways without having any visual impact (visual acuity, visual field, ocular motor examination), yearly or 2-yearly ophthalmologic

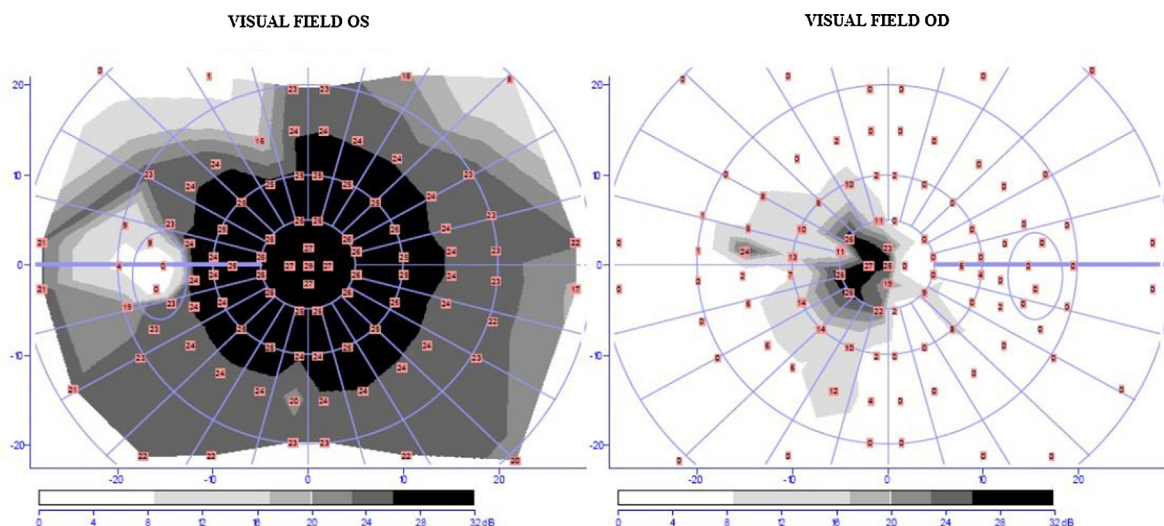


Fig. 5. Visual field assessment illustrating junctional Traquair syndrome (junctional scotoma). Points not perceived are shown in white. There is a huge right-eye scotoma, leaving an island of nasal vision; in the left eye, there is a superior temporal scotoma.

monitoring according to tumor growth kinetics is recommended. The risk for visual function is slight, except in case of pituitary apoplexy.

If visual function is impaired, treatment is often considered. If general health status precludes etiological treatment, ophthalmologic examination should be repeated within 3 to 4 months.

The kinetics of post-surgical visual recovery comprises several phases. Kerrison et al. [4] identified three. The early phase, up to 1 month postoperatively, corresponds pathophysiologically to release of the conduction block caused by the compression; cases of severe visual field defect resolving by 1 week have been described. The second phase, between 1 and 4 months, is the phase of remyelination. In the late phase, between 4 months and 3 years, improvement continues, although less strongly, thanks to the same mechanisms plus possible neuronal plasticity effects within the anterior visual pathways. Gnanalingham et al. [5] followed up 41 patients for 5 years, with very precise quantitative study of visual field defect, and found visual field improvement up to end of follow-up, more than 50% of the improvement taking place within 6 months.

The rhythm of postoperative ophthalmologic surveillance has not been a focus of published guidelines. We recommend postoperative consultation at 3 months, then every 4 to 6 months until visual function stabilizes; annual examination may then be pursued. Each consultation should include visual acuity assessment, pupil and fundus examination, visual field test and ocular motor examination as well as standard ophthalmologic examination. It is important to perform all visual field tests in the same place and on the same apparatus, to allow comparison.

2.5. Prognostic factors

Numerous prognostic factors for visual recovery have been studied, but with contradictory findings. The most reliable prognostic factor to date would seem to be RNFL on OCT [6]: the thinner the RNFL at diagnosis, the greater the optic atrophy and the greater the expected visual defect after treatment.

In a series of 37 eyes in patients presenting pituitary adenoma in contact with the anterior visual pathways and operated on by a trans-sphenoidal approach, RNFL was strongly prognostic of visual field recovery at 3 months: complete recovery of defect at 3 months was associated with RNFL not significantly different than controls, whereas eyes without recovery at 3 months had significantly thinner RNFL than control eyes, eyes with 3-month recovery or eyes without initial defect despite adenoma contact with the anterior visual pathways. The prognostic value of the RNFL was thus established: for the mid-RNFL, the odds ratio for complete recovery of visual field defect at 3 months was 1.29 per 1μ increment ($P = 0.037$). This effect was independent of the effects of age and interval between symptom onset and surgery on multivariate analysis. The inferior RNFL showed very strong prognostic value, with an odds ratio of 6.31 ($P = 0.0001$) per 1μ increment [6].

Reported predictive values of preoperative visual field defect severity for poor postoperative recovery are variable [3,5]. Good preoperative acuity is predictive of good final recovery of acuity according to certain reports [3] but not others [7], and the situation is the same for age [3,5–7]. Preoperative symptom duration has a negative impact on recovery according to certain studies [6], but appeared correlated with severity of preoperative deficit in others [3]. Non-functioning tumors showed variable association with poorer recovery [3,8].

Electrophysiologically, the N95 component of the pattern-electroretinogram (ERG) reflects ganglion-cell activity in the central 15° of the visual field. A study of patients operated on via an endocranial approach or endoscopically for various types of sellar region tumor (meningioma, adenoma) compressing the chiasm [9] reported a probability of postoperative improvement in the visual field of 26.97% when the preoperative N95/P50 ratio was abnormal, versus 64.91% in case of normal ratio. More recently, another flash-ERG parameter reflecting ganglion-cell activity, the photopic negative response (PhNR), was studied, again in patients with various types of sellar tumor operated on via an endocranial approach or endoscopically [10]; the ratio

between PhNR and B-wave amplitude correlated strongly with visual field defect severity at 3 months. Electrophysiological assessment, however, probably gives more negative results than OCT, being a functional approach that takes account not only of the lack of function in ganglion cells that have actually degenerated but also of dysfunction at potentially reversible stages.

3. Ocular motor impairment

Ocular motor impairment associated with large pituitary adenoma is of three types: ocular motor restriction (1 or both eyes moving poorly in certain directions of gaze), which is rare compared to visual field defect (<5% of cases) other than in the particular context of pituitary apoplexy [11]; even rarer, abnormal eye movement, notably see-saw nystagmus; and dorsal midbrain syndrome, in very large tumors compressing the upper brainstem.

3.1. Parenthesis: dysphoric diplopia without ocular motor restriction

Before turning to true ocular motor impairment, a reminder should be given of the frequent onset of episodes of diplopia without ocular motor restriction, associated with visual field disorders preventing effective fusion of images from the two eyes. Diplopia without ocular motor restriction is more frequent than ocular motor restriction [12] and is known as “hemifield slide”. From the images coming from either eye, the brain superimposes the visual fields areas common to the two. This enables perfect alignment of the eyes, so that the corresponding retinal areas in effect perceive one and the same image. In bitemporal hemianopsia, there is no longer a shared area of vision, the right eye perceiving only the left hemifield and vice-versa. This prevents the motor command of alignment, and each eye falls into its anatomic rest position, which varies from individual to individual. In exophoria (each eye tending to turn to outward), patients perceive a central overlap between the nasal hemifields without being able to achieve fusion, inducing a sensation of diplopia. In esophoria (the eyes spontaneously tending to cross), patients may perceive separate nasal hemifields, resulting in a vertical central scotoma in binocular vision [13].

3.2. Anatomic bases of ocular motor impairment

Ocular motor restriction is due to lesions to ocular motor nerves III (common ocular motor nerve), IV (trochlear nerve) and VI (abducens nerve) between brainstem and orbit. In pituitary adenoma, the lesion is usually in the cavernous sinus (Fig. 6).

The cavernous sinus is a large confluence of veins lying on either side of the sella turcica, which contains the pituitary gland. It constitutes the lateral wall of the sella. The ophthalmic veins and sphenoparietal sinus in particular terminate in the cavernous sinus. There are vascular (internal carotid artery) and neural structures (all three ocular motor nerves [III, IV and VI], the ophthalmic nerve [V1], the inferolateral portion of the maxillary nerve [V2] and the sympathetic contingent innervating the

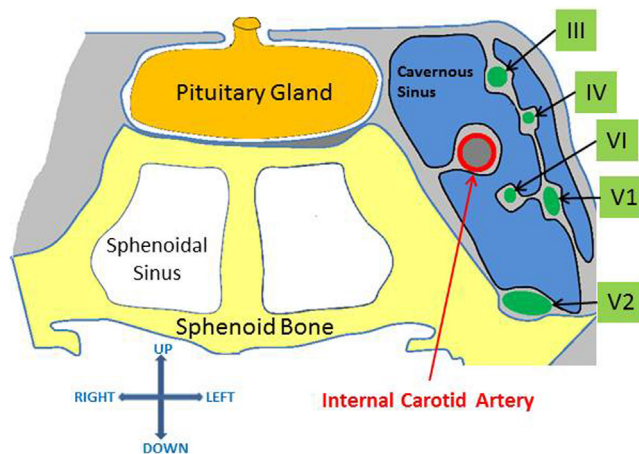


Fig. 6. Diagram of cavernous sinus, coronal cross-section.

eye [14–16] and inducing Bernard Horner syndrome in case of lesion).

See-saw nystagmus is due to compression of the diencephalic-mesencephalic region at the interstitial nucleus of Cajal or rostral interstitial nucleus of the medial longitudinal fasciculus (Fig. 7) [17–19]. These nuclei are involved in ocular motor control.

Finally, dorsal midbrain syndrome results from compression of the superior and posterior midbrain, which may also be associated with hydrocephalus by compression of the 3rd ventricle.

3.3. Pathophysiology of ocular motor impairment

It should be borne in mind that ocular motor impairment strongly suggests pituitary apoplexy, being exceptionally found at diagnosis of macroadenoma [11]. Several pathophysiological hypotheses have been put forward to explain ocular motor nerve involvement. One concerns direct compression of the nerve by the tumor, or indirect compression through the wall of the cavernous sinus [20]; the indirect mechanism is more likely in case of rapid tumor growth, as in apoplexy, following intra-tumoral hemorrhage or tumoral ischemic infarction. Location is usually in the cavernous sinus, but some authors have hypothesized nerve compression in the oculomotor trigone (roof of the cavernous sinus), limited laterally by the anterior petroclinoid ligament, medially by a line above the interclinoid ligament and posteriorly by the posterior petroclinoid ligament [16], supposedly a dural weak-spot [21]. Finally, in very large tumors, ocular motor nerve compression may also be exerted in the brainstem or subarachnoid spaces [22]. Other hypotheses appeal to possible infiltration of the nerve by the tumor [22], or ischemia by vascular occlusion of the perforating arteries [23].

Of the 3 ocular motor nerves (III, IV and VI), the common ocular motor nerve (III) is the most frequently involved [24]. It enters the cavernous sinus via the oculomotor trigone with a mediolateral course towards the superior orbital fissure. At the roof of the sinus, where III enters, there is a whole cistern of cerebrospinal fluid (as the nerve is accompanied by an arachnoid sheet), and this cistern represents a possible route for tumor infiltration or extension [22,25,26]. Moreover, III lies in the same

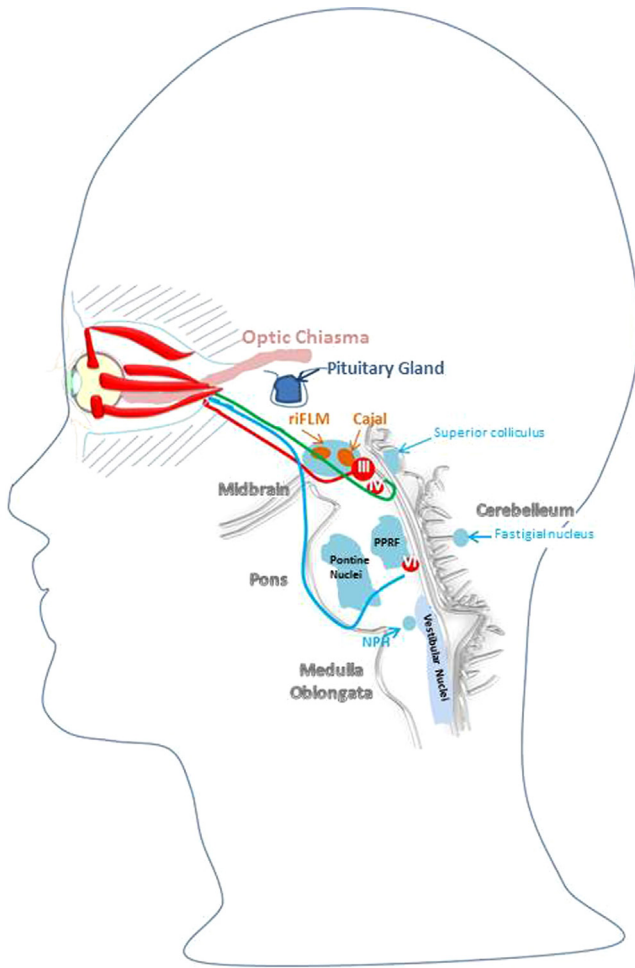


Fig. 7. Anatomic diagram of brainstem ocular motor centers. For easier reading, the ocular motor nerve course has been shifted downward at the pituitary gland: the nerves actually pass much nearer the gland, in the cavernous sinus, on either side. riMLF: rostral interstitial nucleus of the medial longitudinal fasciculus; PPRF: paramedian pontine reticular formation; NPH: nucleus prepositus hypoglossi.

horizontal plane as the pituitary gland and is the most medial ocular motor nerve (Fig. 8); pressure induced by lateral extension of the tumor is thus exerted on III at an early stage [23,27–30]. However, III is rarely involved in isolation, although some such cases have been reported [23,31–34]. Nerves IV and VI are less often involved than III [24,28,35]. IV is protected at its entry into the cavernous sinus by a doubling of the dura mater, and VI enters via an osteodural canal through the posterior wall, Dorello's canal [28,36,37]. Fourth and VIth nerves are mostly affected in case of massive compression of the cavernous sinus, involving all the ocular motor nerves [38].

3.4. Initial ocular motor assessment

3.4.1. Ocular motor restriction

Ocular motor restriction leads to diplopia when gaze is focused in the field of action of the paralyzed muscle. However, this is only true if visual acuity is good enough in both eyes.

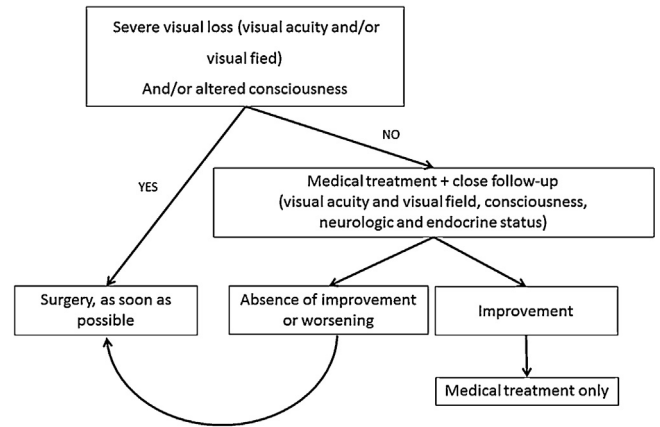


Fig. 8. Decision tree for the management of pituitary apoplexy, taken from UK Guidelines for management of pituitary apoplexy. The authors do not see isolated ocular motor palsy as an indication for surgery, even without improvement over the first days of observation.

[41].

Nerve III innervates the superior, inferior and medial rectus muscles, the inferior oblique, levator palpebrae superioris (levator muscle) and iris sphincter muscle. Complete nerve III palsy induces complete ptosis with paralyzed elevation, lowering and adduction of the eye and mydriasis. Partial nerve III palsy is frequent, inducing partial or complete palsy in only some of the muscles innervated by the nerve. Nerve IV innervates the superior oblique, and palsy impairs lowering of the eye in low and medial gaze. Nerve VI innervates the lateral rectus and palsy induces abduction deficit.

The initial examination raises the question of “possible diplopia” and ocular motor examination is performed as part of ophthalmologic assessment in sellar tumor. The important parameters for assessment here are version (conjoint movement of both eyes), duction (movement eye by eye), cover test measuring the deviation with prisms and pupil examination. The Hess-Weiss coordimetric graph reproducibly measures ocular motor defects and may be combined with cover test.

3.4.2. See-saw nystagmus

See-saw nystagmus comprises a cycle of elevation and intorsion of one eye with synchronous depression and extorsion of the other, followed by an inverse cycle. It may induce symptoms such as oscillopsia (trembling image sensation) [39].

3.4.3. Other manifestations

Certain large tumors may also induce hydrocephalus, posterior expansion toward the 3rd ventricle blocking cerebrospinal fluid circulation. Papilloedema is then due more to this hydrocephalus than to tumor volume as such.

There may also exceptionally be dorsal midbrain syndrome, associating one or more of the following: Parinaud's syndrome (gaze elevation defect); nystagmus retractorius; abnormal eyelid position (ptosis or retraction of the upper eyelids); abnormal pupil size, pupil dissociation in light and in convergence; accommodation disorder; convergence disorder; and skew deviation [40].

3.5. Follow-up

Follow-up examinations are similar to initial assessment: history taking and ocular motor, vision and fundus examination, Hess-Weiss coordimetric graph and visual field test. In case of major discrepancy between the two eyes, occluding one eye is the only means of relieving the patient's diplopia. If discrepancy persists long after treatment, surgical displacement of the ocular motor muscles may, very exceptionally, be proposed. If the discrepancy is moderate, prisms can be adapted: provisionally stuck on the patient's lenses at first and then definitively included in the lenses when stability is achieved at a suitable interval after treatment. In all cases, the objective is to relieve diplopia in primary position and in lowered gaze, but it is usually not possible to restore single vision in all directions of gaze.

3.6. Prognostic factors

The prognostic factors for ocular motor disorder associated with non-secreting pituitary adenoma are not known except in the case of pituitary apoplexy (see below).

4. Pituitary apoplexy

Neuro-ophthalmologic signs are in the forefront of the clinical presentation of pituitary apoplexy, with sudden visual loss and/or ocular motor palsy. Frequently, headache, which may often be intense and sudden, is associated. Visual impairment is found in 75% of cases, secondary to a sudden increase in the size of the pre-existing adenoma [41]. It is, however, noteworthy that there is often already optic atrophy at diagnosis. For example, optic atrophy was found in 7/14 cases of pituitary apoplexy inducing total visual loss [42]; as several months of anterior visual pathway compression are needed to induce optic atrophy, it is easy to see that visual impairment is already advanced although not consciously experienced by the patient at onset of apoplexy. Ocular motor palsy occurs in almost 70% of cases [41]. The third nerve is the most frequently involved, in 50% of patients with cranial nerve involvement, followed by VIth nerve palsy, then IVth nerve palsy, then Vth nerve palsy [43]. Nerve dysfunction is caused by compression of the cavernous sinus and the nerves within it secondary to a sudden increase in tumor size. Unlike the anterior visual pathways, the ocular motor nerves, when affected, induce diplopia, which quickly leads to consultation. As most patients are asymptomatic prior to pituitary apoplexy, it may be supposed that the ocular motor nerves presented little or no dysfunction prior to this acute event.

The type and severity of neuro-ophthalmologic involvement guide treatment options: non-operative or surgical, and time to surgery if any. However, given the rarity of pituitary apoplexy, no prospective studies have been feasible; the retrospective studies had several biases: the severity of neuro-ophthalmologic involvement differed between surgical and non-operative groups, vitiating prognostic comparison; time to surgery was highly variable, and reasons for postponing surgery were not always explained; finally, almost all series were small.

Surgery is almost certainly indicated in severe neuro-ophthalmologic involvement (affecting acuity and/or visual field), showing progression or associated with disorder of consciousness; in "moderate neuro-ophthalmologic involvement", on the other hand, there is no consensus as to the role of simple medical management, and indeed the concept of "moderate neuro-ophthalmologic involvement" is not clearly defined.

Ayuk et al., in 2004 [44], seemed to validate medical management of mild neuro-ophthalmologic involvement. Non-operative treatment was implemented in 33 pituitary apoplexy patients, with surgery reserved for visual deterioration or worsened neurologic status. Surgery was performed within 22 days in 14 out of the 15 cases managed surgically; 18 patients were managed medically. Seven of the 18 patients managed medically presented with ocular motor palsy and 6 with visual field defect; all showed complete recovery. Eight of the 15 patients managed surgically showed ocular motor involvement, with total regression in 63% of cases, and 7 showed visual field defect, resolved in 57% of cases at end of follow-up (mean follow-up, 3.78 years; range, 0.4–10.1 years). Severity of ophthalmologic involvement was not compared between groups, preventing comparison of treatments but nevertheless validating the safety of a strategy reserving surgery to cases of clinical deterioration. Other studies seem to show similar results [45].

A retrospective study by Leyer et al. in 2011 [46] included 44 patients, managed surgically or medically, with 4 undergoing secondary surgery after primary medical care. Primary surgery was indicated for severity of visual impairment or consciousness disorder, although the criteria of visual severity were not specified. Again, medical management seemed to provide satisfactory neuro-ophthalmologic results, but comparison is meaningless given the baseline differences between groups.

The interest of early intervention when surgery is indicated is more a matter of common sense for a compressive pathology such as pituitary apoplexy than an evidence-based attitude. The Oxford series [47] was one of the first to compare neuro-ophthalmologic performances between early (within 8 days of onset) and late surgery (at 9–34 days). In this retrospective series, medical management was reserved to cases free of visual involvement. Recovery of visual acuity was complete in 100% of patients operated on within 8 days but only 46% of those operated on later, 31% showing partial recovery and 23% no recovery. The evolution of the visual field and ocular motor function also seemed more favorable with early surgery. However, the main bias of this retrospective study was a lack of data on the degree of neuro-ophthalmologic deficit according to group, vitiating comparison.

Woo et al., in 2010, reported similar results in a retrospective series of 12 patients, but again without data on baseline deficit between the early and late surgery groups [43]. There was a significant correlation ($P=0.0286$) between apoplexy-to-surgery interval and time to postoperative cranial nerve recovery, arguing for early intervention. Kim et al., in 2007, also supported the hypothesis that time to surgery is a prognostic factor for speed of recovery of ocular motor palsy [37].

Other than early treatment, Chuang et al., in 2011, also suggested that absence of afferent pupillary defect and low-intensity

ocular motor signs are factors of good ocular motor recovery [48].

In complete loss of vision (negative light perception) in acute pituitary apoplexy, visual prognosis is poor, but a certain degree of recovery may occur [49]. In a retrospective series of 7 patients (14 eyes) with complete loss of vision secondary to pituitary apoplexy [42], optic atrophy was found at diagnosis in 7 patients, testifying to optic nerve involvement prior to apoplexy; 3 eyes achieved final 10/10 acuity. Recovery seemed to be better with early surgery.

In the light of the scientific evidence available and the experience of physicians and surgeons treating pituitary apoplexy, the UK Guidelines for Management of Pituitary Apoplexy [41] recommend the decision tree shown in Fig. 8.

5. Conclusion

Management of pituitary adenoma is necessarily multidisciplinary. It is therefore important for each endocrinologist to be in close contact with a local ophthalmologist aware of the issues involved in pituitary pathology. Ophthalmologic assessment will thus be earlier and complete, including visual field test and ocular misalignment measures. The patient's file will be collated by the ophthalmologist, who should take care to distinguish the respective roles of the pituitary adenoma and other concomitant ophthalmic pathologies. Treatment is basically etiological, but symptomatic treatment, notably in case of diplopia, may be undertaken by the ophthalmologist and assistant.

Disclosure of interest

The authors declare that they have no conflicts of interest concerning this article.

References

- [1] Ciric I, Mikhael M, Stafford T, Lawson L, Garces R. Transsphenoidal microsurgery of pituitary macroadenomas with long-term follow-up results. *J Neurosurg* 1983;59(3):395–401.
- [2] Mortini P, Losa M, Barzaghi R, Boari N, Giovanelli M. Results of transsphenoidal surgery in a large series of patients with pituitary adenoma. *Neurosurgery* 2005;56(6):1222–33 [Discussion 33].
- [3] Cohen AR, Cooper PR, Kupersmith MJ, Flamm ES, Ransohoff J. Visual recovery after transsphenoidal removal of pituitary adenomas. *Neurosurgery* 1985;17(3):446–52.
- [4] Kerrison JB, Lynn MJ, Baer CA, Newman SA, Bioussé V, Newman NJ. Stages of improvement in visual fields after pituitary tumor resection. *Am J Ophthalmol* 2000;130(6):813–20.
- [5] Gnanalingham KK, Bhattacharjee S, Pennington R, Ng J, Mendoza N. The time course of visual field recovery following transsphenoidal surgery for pituitary adenomas: predictive factors for a good outcome. *J Neurol Neurosurg Psychiatry* 2005;76(3):415–9.
- [6] Jacob M, Raverot G, Jouanneau E, Borson-Chazot F, Perrin G, Rabilloud M, Tilikete C, Bernard M, Vighetto A. Predicting visual outcome after treatment of pituitary adenomas with optical coherence tomography. *Am J Ophthalmol* 2009;147(1):64–7000.
- [7] Sullivan LJ, O'Day J, McNeill P. Visual outcomes of pituitary adenoma surgery. *St. Vincent's Hospital 1968-1987. J Clin Neuroophthalmol* 1991;11(4):262–7.
- [8] Trautmann JC, Laws Jr ER. Visual status after transsphenoidal surgery at the Mayo Clinic, 1971–1982. *Am J Ophthalmol* 1983;96(2):200–8.
- [9] Parmar DN, Sofat A, Bowman R, Bartlett JR, Holder GE. Visual prognostic value of the pattern electroretinogram in chiasmal compression. *Br J Ophthalmol* 2000;84(9):1024–6.
- [10] Moon CH, Hwang SC, Kim BT, Ohn YH, Park TK. Visual prognostic value of optical coherence tomography and photopic negative response in chiasmal compression. *Invest Ophthalmol Vis Sci* 2011;52(11):8527–33.
- [11] Lyle TK, Clover P. Ocular symptoms and signs in pituitary tumours. *Proc R Soc Med* 1961;54:611–9.
- [12] Hollenhorst RW, Younge BR. In: Kohler PO, Ross GT, editors. *Diagnosis and treatment of pituitary tumors: ocular manifestations produced by adenomas of the pituitary gland: analysis of 1000 cases.* Amsterdam: Excerpta Medica; 1973.
- [13] Newman NJ. Chiasm, parachiasmatic syndromes, retrochiasm, and disorders of higher visual functions. In: Thomas L, editor. *Slamovits, neuro-ophthalmology, volume 6.* London: Mosby-Year Book; 1994.
- [14] Harris FS, Rhoton AL. Anatomy of the cavernous sinus. A microsurgical study. *J Neurosurg* 1976;45(2):169–80.
- [15] Johnston JA, Parkinson D. Intracranial sympathetic pathways associated with the sixth cranial nerve. *J Neurosurg* 1974;40(2):236–43.
- [16] Umansky F, Nathan H. The lateral wall of the cavernous sinus. With special reference to the nerves related to it. *J Neurosurg* 1982;56(2):228–34.
- [17] Bentley CR, Bronstein AM, Faldon M, Farmer S, Gresty MA, Matthews TD, Paine M, Plant GT, Riordan-Eva P. Fast eye movement initiation of ocular torsion in mesodiencephalic lesions. *Ann Neurol* 1998;43(6):729–37.
- [18] Kanter DS, Ruff RL, Leigh RJ, Modic M. See-saw nystagmus and brainstem infarction: MRI findings. *Neuroophthalmology* 1987;7(5):279–83.
- [19] Ranalli PJ, Sharpe JA, Fletcher WA. Palsy of upward and downward saccadic, pursuit, and vestibular movements with a unilateral midbrain lesion: pathophysiologic correlations. *Neurology* 1988;38(1):114–22.
- [20] Walsh FB. Bilateral total ophthalmoplegia with adenoma of the pituitary gland; report of two cases; an anatomic study. *Arch Ophthalmol* 1949;42(5):646–54 [illust.].
- [21] Kawase T, van Loveren H, Keller JT, Tew JM. Meningeal architecture of the cavernous sinus: clinical and surgical implications. *Neurosurgery* 1996;39(3):527–34 [Discussion 34–6].
- [22] Jefferson G. Extrasellar Extensions of pituitary adenomas: (Section of Neurology). *Proc R Soc Med* 1940;33(7):433–58.
- [23] Saul RF, Hilliker JK. Third nerve palsy: the presenting sign of a pituitary adenoma in five patients and the only neurological sign in four patients. *J Clin Neuroophthalmol* 1985;5(3):185–93.
- [24] Wray SH. Neuro-ophthalmologic manifestations of pituitary and parasellar lesions. *Clin Neurosurg* 1977;24:86–117.
- [25] Cairns H. Peripheral ocular palsies from the neurosurgical point of view. *Trans Ophthalmol Soc UK* 1938;58:464–82.
- [26] Symonds C. Ocular palsy as the presenting symptom of pituitary adenoma. *Bull Johns Hopkins Hosp* 1962;111:72–82.
- [27] Lau KK, Joshi SM, Ellamushi H, Afshar F. Isolated bilateral oculomotor nerve palsy in pituitary apoplexy: case report and review. *Br J Neurosurg* 2007;21(4):399–402.
- [28] Robert Jr CM, Feigenbaum JA, Stern EW. Ocular palsy occurring with pituitary tumors. *J Neurosurg* 1973;38(1):17–9.
- [29] Rossitch Jr E, Carrazana EJ, Black PM. Isolated oculomotor nerve palsy following apoplexy of a pituitary adenoma. *J Neurosurg Sci* 1992;36(2):103–5.
- [30] Trumble HC. Pituitary tumours; observations on large tumours which have spread widely beyond the confines of the sella turcica. *Br J Surg* 1951;39(153):7–24.
- [31] Hsu TH. Sudden onset of unilateral third nerve paresis in a patient with Cushing syndrome. *Arch Neurol* 1977;34(3):196–8.
- [32] Kobayashi H, Kawabori M, Terasaka S, Murata J, Houkin K. A possible mechanism of isolated oculomotor nerve palsy by apoplexy of pituitary adenoma without cavernous sinus invasion: a report of two cases. *Acta Neurochir (Wien)* 2011;153(12):2453–6 [Discussion 6].
- [33] Wykes WN. Prolactinoma presenting with intermittent third nerve palsy. *Br J Ophthalmol* 1986;70(9):706–7.
- [34] Yen MY, Liu JH, Jaw SJ. Ptosis as the early manifestation of pituitary tumour. *Br J Ophthalmol* 1990;74(3):188–91.

- [35] Lopez R, David NJ, Gargano F, Post JD. Bilateral sixth nerve palsies in a patient with massive pituitary adenoma. *Neurology* 1981;31(9):1137–8.
- [36] Iaconetta G, Fusco M, Cavallo LM, Cappabianca P, Samii M, Tschabitscher M. The abducens nerve: microanatomic and endoscopic study. *Neurosurgery* 2007;61(3 Suppl.):7–14 [Discussion].
- [37] Kim SH, Lee KC, Kim SH. Cranial nerve palsies accompanying pituitary tumour. *J Clin Neurosci* 2007;14(12):1158–62.
- [38] Petermann SH, Newman NJ. Pituitary macroadenoma manifesting as an isolated fourth nerve palsy. *Am J Ophthalmol* 1999;127(2):235–6.
- [39] Gittinger Jr JW. Ophthalmological evaluation of pituitary adenomas. In: *The Pituitary Adenoma*. Springer; 1980. p. 259–86.
- [40] Chhabra VS, Newman NJ. The neuro-ophthalmology of pituitary tumors. *Compr Ophthalmol Update* 2006;7(5):225–40 [Discussion 41–2].
- [41] Rajasekaran S, Vanderpump M, Baldeweg S, Drake W, Reddy N, Lanyon M, Markey A, Plant G, Powell M, Sinha S, Wass J. UK guidelines for the management of pituitary apoplexy. *Clin Endocrinol (Oxf)* 2011;74(1):9–20.
- [42] Agrawal D, Mahapatra AK. Visual outcome of blind eyes in pituitary apoplexy after transsphenoidal surgery: a series of 14 eyes. *Surg Neurol* 2005;63(1):42–6 [Discussion 6].
- [43] Woo HJ, Hwang JH, Hwang SK, Park YM. Clinical outcome of cranial neuropathy in patients with pituitary apoplexy. *J Korean Neurosurg Soc* 2010;48(3):213–8.
- [44] Ayuk J, McGregor EJ, Mitchell RD, Gittoes NJ. Acute management of pituitary apoplexy—surgery or conservative management? *Clin Endocrinol (Oxf)* 2004;61(6):747–52.
- [45] Maccagnan P, Macedo CL, Kayath MJ, Nogueira RG, Abucham J. Conservative management of pituitary apoplexy: a prospective study. *J Clin Endocrinol Metab* 1995;80(7):2190–7.
- [46] Leyer C, Castinetti F, Morange I, Gueydan M, Oliver C, Conte-Devolx B, Dufour H, Brue T. A conservative management is preferable in milder forms of pituitary tumor apoplexy. *J Endocrinol Invest* 2011;34(7):502–9.
- [47] Randevara HS, Schoebel J, Byrne J, Esiri M, Adams CB, Wass JA. Classical pituitary apoplexy: clinical features, management and outcome. *Clin Endocrinol (Oxf)* 1999;51(2):181–8.
- [48] Chuang CC, Chen E, Huang YC, Tu PH, Chen YL, Pai PC. Surgical outcome of oculomotor nerve palsy in pituitary adenoma. *J Clin Neurosci* 2011;18(11):1463–8.
- [49] Muthukumar N, Rossette D, Soundaram M, Senthilbabu S, Badrinarayanan T. Blindness following pituitary apoplexy: timing of surgery and neuro-ophthalmic outcome. *J Clin Neurosci* 2008;15(8):873–9.