

# Anatomy of optic nerve radiations as assessed by static perimetry and MRI after tailored temporal lobectomy

P Krolak-Salmon, M Guenot, C Tiliket, J Isnard, M Sindou, F Mauguiere, A Vighetto

## Abstract

**Aims**—To determine the course of optic nerve radiations in the temporal lobe, especially their retinotopic organisation and the anterior limit of the Meyer's loop. **Methods**—18 adult patients who had undergone a tailored temporal lobectomy for epilepsy were included in this study between 1994 and 1998. The rostrocaudal extent of the lateral temporal lobe resection assessed intraoperatively by the surgeon and by postoperative MRI was compared with the postoperative visual fields determined by automated static perimetry (ASP).

**Results**—15 patients (83%) presented a postoperative visual field deficit (VFD) confined to the superior homonymous field contralateral to the side of the resection. All degrees from a minimal upper field loss to a complete quadrantanopia were observed. The VFDs were somewhat stereotyped, predominating along the vertical meridian. The smallest anteroposterior resection resulting in a VFD was limited to 20 mm from the tip of the temporal lobe. A relation was observed between the extent of the lateral resection in front of the second and third convolutions and the occurrence and extent of postoperative VFDs. No patient reported persisting subjective visual impairment.

**Conclusion**—The high frequency of postoperative VFDs appears to be due to the greater sensitivity of ASP. The characteristics of the stereotyped VFDs allow new conclusions about the course and retinotopy of optic nerve radiations. The anterior limit of Meyer's loop is likely to be located more rostrally than previously believed.

(Br J Ophthalmol 2000;84:884–889)

Visual field deficits (VFDs) after surgical, tumoral, or vascular lesions of the temporal lobe have been studied for a long time. In spite of the classic description of the anterior course of visual pathways in the temporal lobe,<sup>1,2</sup> the relation between these fibres and the temporal horn of the lateral ventricle, and the retinotopic organisation of optic nerve radiations remain to be specified. No study combining automated static perimetry and anatomical evaluation of the lesion by magnetic resonance imaging (MRI) is available in the literature. We present a study of VFDs after temporal lobe surgery for medically refractory epilepsy per-

formed between 1994 and 1998. In contrast with previous studies, an automated static perimetry (ASP) and a postoperative MRI were performed in all cases, allowing a thorough description of the relation between VFDs and well defined resections of the temporal lobe.<sup>3,4</sup> This study aimed at (1) gathering further anatomical knowledge about the temporal course of the optic nerve radiations, and (2) evaluating the prevalence and characteristics of postoperative VFDs.

## Subjects and methods

All patients were referred for medically refractory epilepsy to the epilepsy department of the neurological hospital in Lyons, France. Fifteen patients presented with a temporal lobe epilepsy, two patients with a frontotemporal lobe epilepsy, and one patient with a multifocal epilepsy. The temporal surgery was considered as a palliative treatment in these three latter cases. Video EEG using scalp and, if needed, depth stereotactic recordings (in 12 patients) was used to localise the epileptogenic area. Patients with expanding lesions or gross cerebral damage of the temporal lobe on preoperative MRI or postoperative histological analysis, patients with ophthalmological disease, and patients who were unable to cooperate reliably during the visual field examination were excluded. Eighteen right handed patients (12 women, six men; age 20–44, mean 36 years) met these criteria. Temporal lobectomy was performed on the right side in 11 cases and on the left side in seven cases. All patients remained on antiepileptic medication after surgery.

All surgical procedures were performed at the neurological hospital between 1994 and 1998 by the same surgeon (MS) under general anaesthesia. The extent of removal, progressing from anterior to posterior in the temporal lobe, was tailored in each case according to findings on video-EEG monitoring using scalp and depth electrodes, to cerebral MRI, ictal, and interictal single photon emission tomography and/or positron emission tomography, and to cerebral angiography. After removal of the pole, the temporal horn of the lateral ventricle was entered by a direct lateral approach. An uncoamygdalohippocampotomy with resection of the parahippocampal gyrus and removal of a variable amount of the lateral part of the temporal lobe, was performed. The length of the resection of each temporal convolution was measured from the temporal tip intraoperatively by the surgeon and compared with

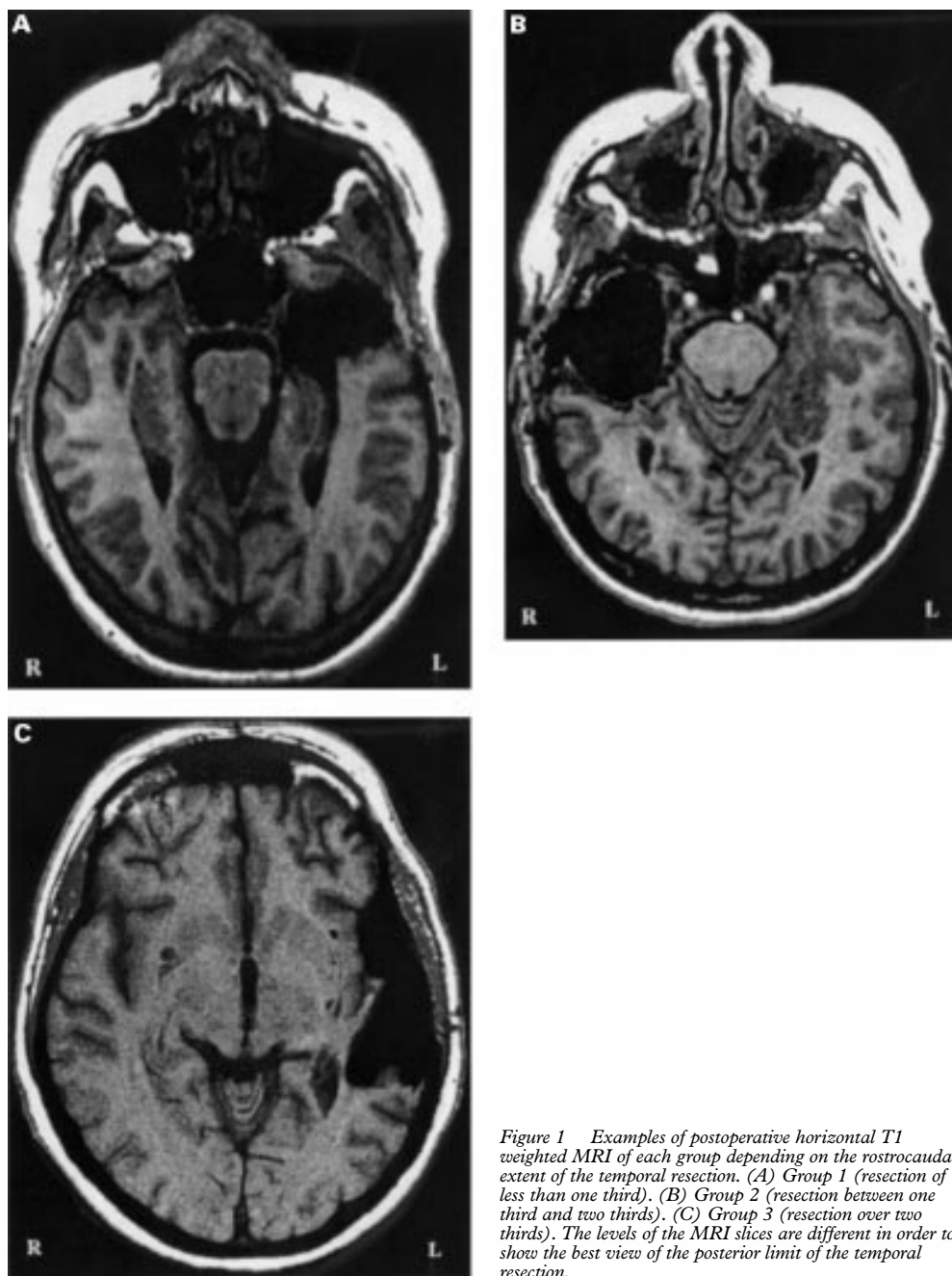
Department of  
Neuro-ophthalmology,  
P Wertheimer  
Neurological Hospital,  
Lyons, France  
P Krolak-Salmon  
C Tiliket  
A Vighetto

Department of  
Neuro-surgery  
M Guenot  
M Sindou

Department of  
Epileptology  
J Isnard  
F Mauguiere

Correspondence to:  
P Krolak-Salmon, Service de  
Neuro-ophthalmologie,  
Hopital Neurologique et  
Neuro-chirurgical P  
Wertheimer, 59 Boulevard  
Pinel, 69394 Lyon cedex 03,  
France  
pkrolak@club-internet.fr

Accepted for publication  
25 February 2000



*Figure 1* Examples of postoperative horizontal T1 weighted MRI of each group depending on the rostrocaudal extent of the temporal resection. (A) Group 1 (resection of less than one third). (B) Group 2 (resection between one third and two thirds). (C) Group 3 (resection over two thirds). The levels of the MRI slices are different in order to show the best view of the posterior limit of the temporal resection.

postoperative MRI slices aligned parallel to the horizontal AC-PC plan. Intraoperative evaluation of the lateral resection and postoperative MRI measurement were incongruous in only two cases. In these two cases, the anatomical considerations of the lateral resection were based on MRI measurements. In our series, from 20 mm to 60 mm of the lateral temporal lobe were resected on the language dominant side and from 20 mm to 70 mm on the language non-dominant side.

Preoperative automated static perimetry was performed in six patients and did not show any VFD. Postoperative static visual fields were evaluated with a mean delay of 18.4 (SD 14) weeks. ASP was mapped on the vision monitor (Metrovision) with a standardised program using size 3 white targets with a maximal luminance of 318 cd/m<sup>2</sup> and a screen luminance of

10 cd/m<sup>2</sup>. A suprathreshold strategy (4 dB above the theoretical luminance threshold) for the 94 points tested in the central 30° and a liminal strategy for the foveolar point were used. Eight additional measurements were used to chart the blind spot contour. Testing was always carried out with appropriate acuity correction. In addition, patients were submitted at least 3 months after surgery to a formal questionnaire evaluating subjective visual impairment and its impact on daily life activities.

## Results

The patients were assigned to three different groups depending on the anteroposterior length of the resection of the lateral temporal lobe (especially at the level of the second and the third convolutions) from the tip of the

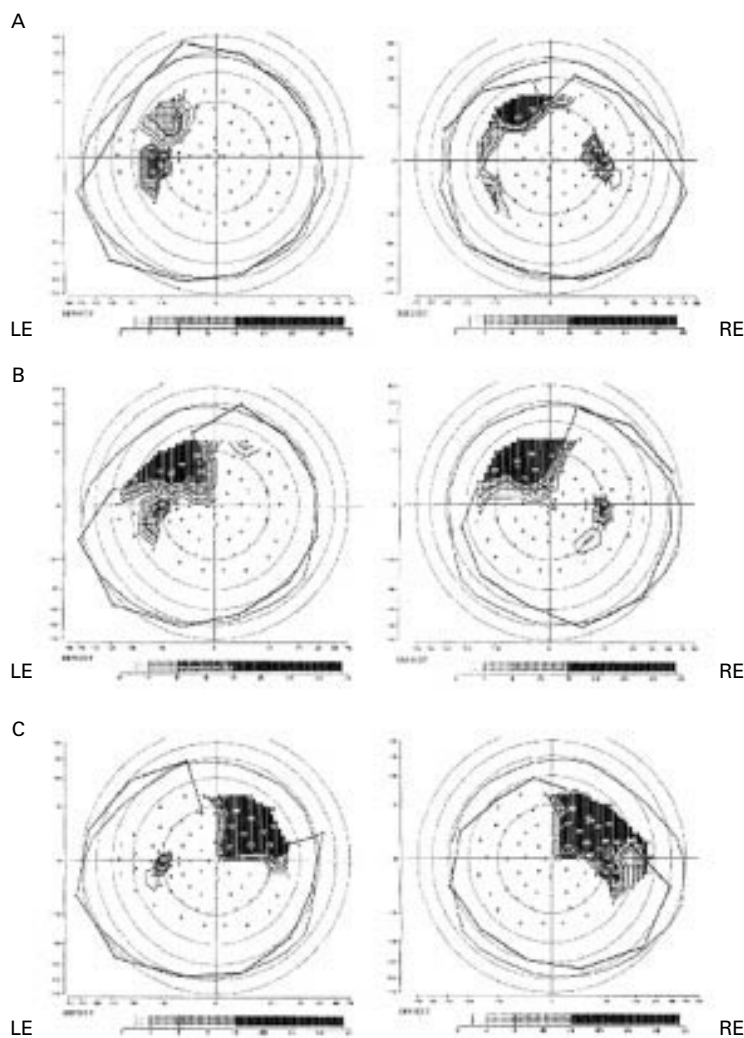


Figure 2 Examples of each type of quadrantanopia defined by the extent of the visual field defect. (A) Left mild quadrantanopia. (B) Left moderate quadrantanopia. (C) Right total quadrantanopia.

temporal lobe. Considering the arbitrary line forming the base of the angular and supramarginal gyri as the posterior surgical limit of the temporal lobe,<sup>5,6</sup> group 1 (three patients) had a resection of less than a third of the anteroposterior length of the lateral part of the temporal lobe (mean 16.7 (SD 5.8) mm), group 2 (four patients) had a resection from one third to less than two thirds (mean 31.3 (2.5) mm), and group 3 (11 patients) had a resection over two thirds of the length of the lateral temporal lobe (mean 51 (10.1) mm) (Fig 1).

The histopathological examination was normal or aspecific in seven patients and revealed a hippocampal sclerosis in seven patients, a dysembryoplastic tumour in one patient, a microhamartoma in two patients, and a cortical dysplasia in one patient.

The overall frequency of postoperative VFDs, all confined to the superior homonymous field contralateral to the side of the resection, was 15 of 18 (83%). The VFDs showed all degrees from a minimal upper field loss to a total quadrantanopia. The postoperative VFDs were classified into three categories depending on the extent of the scotoma: mild quadrantanopias defined by defects of less than

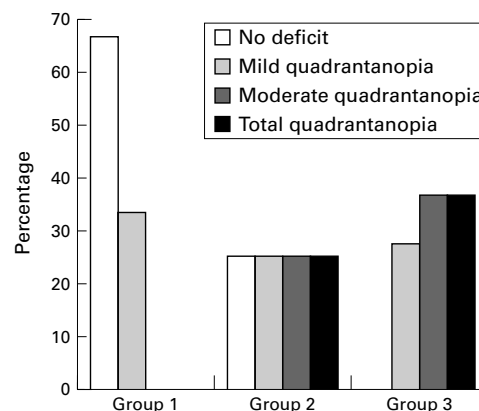


Figure 3 Distribution of the different types of quadrantanopias in the three groups depending on the anteroposterior extent of the lateral temporal resection in front of second and third convolutions. Columns represent the percentage of patients in each group (ordinate) with, respectively, no visual field deficit, mild, a moderate, or a total quadrantanopia (abscissa).

50% of the 30 central degrees of the upper quadrant, moderate quadrantanopias defined by defects of more than 50% of the 30 central degrees, and total quadrantanopias (Fig 2). Five patients had mild quadrantanopia, five had moderate quadrantanopia, and five had total quadrantanopia. The results of visual field analyses depending on the anteroposterior extent of the lateral resection are presented in Figure 3. Two of the three patients in group 1 had no deficit and one patient a mild VFD, the patients in group 2 had variable VFD, and a majority of patients in group 3 presented moderate and total quadrantanopias. The medial margin of the quadrantanopia was generally superimposed to the vertical meridian, whereas the inferior margin usually spared the horizontal meridian and was superimposed to a meridian passing through the fixation point. The isoptres were superimposed on the vertical meridian and separated on the inferior margin. The degree to which the defect may have approached the foveolar point was variable, but in all cases approximated closest the foveolar point along the superior vertical meridian (Fig 2). The horizontal and vertical meridians were overstepped in six patients. The horizontal meridian was overstepped for one eye and the vertical meridian for six eyes. Five of these six patients were in group 3 and one in group 2. The macular region was spared in seven cases and involved in eight cases. Five of these eight patients presented a total quadrantanopia and three a moderate quadrantanopia.

The smallest anteroposterior resection resulting in a field defect (mild quadrantanopia) was limited to 20 mm from the tip—that is, the temporal pole. Two quadrantanopias (one mild and one moderate quadrantanopia) were due to a resection of about 30 mm from the tip of the temporal lobe.

According to the criteria defined by Van Buren and Baldwin,<sup>4</sup> the VFDs were considered incongruous when they were at least 5% larger for one eye than for the other. VFDs appeared congruous in 11 patients and incongruous in four patients. A greater defect was observed in the field of the eye ipsilateral to the

lesion in three patients and in the field of the eye contralateral to the lesion in one patient. No monocular VFD was observed. No modification of visual acuity after temporal lobectomy was observed.

Among patients with VFD who answered the questionnaire (13/15), none reported subjective visual deficit or visual impairment in daily life activities.

The postoperative follow up was longer than a year in 14 patients. Ten patients (71%) were seizure free (class I in Engel classification)<sup>7</sup>; two of these patients had no VFD, one had mild quadrantanopia, four had moderate quadrantanopia, and three patients had total quadrantanopia. The two patients presenting with a frontotemporal epilepsy and the patient with a multifocal epilepsy had a poor surgical outcome (class IV in Engel classification). In the last of these 14 patients the surgical outcome could not be reliably assessed because of his irregular compliance with antiepileptic treatment. In the four remaining patients the outcome was not evaluated because of insufficient follow up.

### Discussion

The absence of expanding lesions modifying the anatomy of the temporal lobe allows us to draw conclusions about the course of optic nerve radiations. In comparison with other studies,<sup>1 2 8</sup> the originality of this study lies in (1) that the variability of the anteroposterior length of the lateral temporal resection was precisely measured by two independent methods, and (2) the postoperative visual field evaluation was assessed by automated static perimetry.

Our finding of a VFD frequency of 83.3% is rather high when compared with previous studies reporting 52% to 83% of VFDs assessed by kinetic perimetry after temporal lobectomy.<sup>1 2 6 8-11</sup> Only Falconer and Wilson<sup>12</sup> reported 100% of VFDs after a series of horizontal sections of the temporal lobe varying from 45–90 mm from the temporal lobe tip. Hughes *et al*<sup>13</sup> described recently 97% (31/32 patients) of VFDs assessed by automated static perimetry after tailored temporal lobe resection ranging between 40 mm and 70 mm from the tip. In their study, the large resections extended caudally to the presumed anterior limit of the optic nerve radiations,<sup>1 5 8 9 13</sup> which explains the high percentage of VFD. Moreover, automated static perimetry may be more sensitive to small VFD than kinetic perimetry performed in all previous reports except the study of Hughes *et al* and ours. Depth electrodes may be discounted because they have not been associated with a VFD.<sup>14 15</sup> In our study, half of the patients (9/18) had a resection of less than 31.3 (SD 2.5) mm from the temporal tip (group 1 and 2)—that is, less than the presumed anterior limit of Meyer's loop.<sup>1 5 8 9 13</sup> Interestingly, four out of nine patients in these two groups had a VFD, mostly a mild or a moderate superior quadrantanopia. Thus, our study shows that limited resections of the anterior part of the temporal lobe—that is, less than 4 cm from the tip, can provoke

VFD detected by automated static perimetry. The risk of VFD appears to be higher when the resection extends posteriorly in the lateral temporal lobe, especially in front of the second and third convolutions. Thus, the frequency of VFD is about 33% in group 1, 75% in group 2, and 100% in group 3. Moreover, in our series, there is a progression in the extent of VFD as one proceeds further posteriorly in the temporal lobe. Katz *et al*<sup>6</sup> have reported a correlation between the presence of a VFD (not the extent of the VFD) and the extent of resection measured by postoperative quantitative MRI analysis. The fact that only one third of our patients had a preoperative automated visual field may be critical, but none of these patients had any VFD. Moreover, visual fields are usually normal in patients with non-expanding epileptogenic lesions of the temporal lobe such as those found in our series, and as reported by Hughes *et al* who performed automated visual field analysis before surgery.<sup>12</sup>

Our findings corroborate the classic data on topography of visual pathways.<sup>3 4 16 17</sup> The visual radiations fan out from the lateral geniculate body round the anterior aspect of the fornix. The most anterior pathways, which carry visual information representing the contralateral upper field, go along the anterosuperior aspect to the tip of the temporal horn before passing backwards, at first lateral to and then beneath the ventricle to end in the calcarine cortex. Therefore, fibres of this anterior bundle are at major risk during anterior temporal resection. The question of the anterior extent of optic nerve radiations has often been debated. Marino and Rasmussen<sup>9</sup> reported VFD with excisions of 30–40 mm. Van Buren and Baldwin<sup>4</sup> supported the view that the most anterior fibres in the optic nerve radiations were lying lateral to the tip of the temporal horn—that is, about 30 mm posterior to the tip of the temporal lobe. Rasmussen suggested that VFDs could be avoided by limiting the extent of the superolateral ventricular opening to 1 cm.<sup>18</sup> One of our cases presented a VFD (mild quadrantanopia) with a resection which did not extend beyond 20 mm, and two cases presented a VFD after a resection extending about 30 mm from the tip. These VFDs were diagnosed respectively 5, 3, and 4½ months after surgery—that is, after the acute period during which oedema can occur. Moreover, postoperative MRI did not show any oedema. These observations indicate that the anterior extent of optic nerve radiations run more rostral than the tip of the temporal horn of the lateral ventricle (Fig 4). They are in accordance with the data from dissection of optic nerve radiations obtained by Ebeling and Reulen<sup>19</sup> in 25 human temporal lobes. These authors reported that the most anterior radiations were lying between 22 and 37 mm (mean 27 (SD 3.5) mm) from the tip of the temporal lobe. However, there may be individual anatomical variation in the spatial distribution of optic radiation fibres in the human temporal lobe. That may explain why, among the two patients without any VFD, one patient was in group 1 (resection of

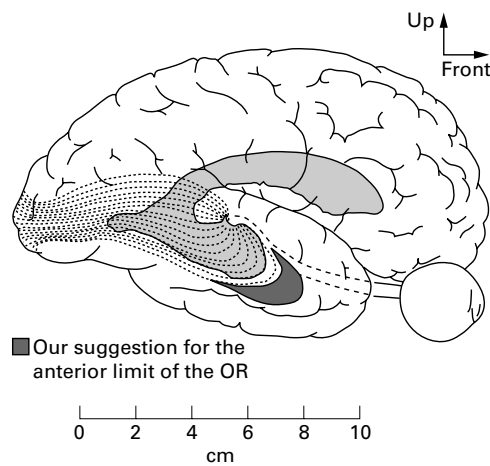


Figure 4 The geniculocalcarine radiation as proposed by Harvey Cushing (dotted lines),<sup>22</sup> completed by our suggestion of a more rostral anterior limit of optic nerve radiations (OR) in the temporal lobe.

less than 20 mm of lateral temporal lobe), whereas the other patient was in group 2 (resection between 20 mm and 40 mm of lateral temporal lobe). So, between these two limits, the occurrence and extent of a postoperative VFD cannot be predicted with precision from the resection volume of the temporal resection.

Incongruous homonymous upper quadrantic defects have been frequently observed with a majority of larger defects in the field of the eye ipsilateral to the lesion.<sup>1 2 4 8-13</sup> A likely explanation is that the optic radiation connected to uncrossed fibres may have a more anterior and lateral course, and thus may be more exposed to damage.<sup>9</sup> Other previous studies have exclusively reported congruous homonymous deficits.<sup>13 16</sup> In our series, the congruity presented no relation with the posterior extent of the resection. Anatomically, the bundles from ipsilateral and contralateral eyes are separated in their trajectory from the geniculate body to the tip of the temporal horn and then tend to fuse when entering the occipital cortex to allow binocular vision. The temporal resection may interrupt the optic nerve radiations (either on their initial posteroanterior course (from the geniculate body to the tip of the temporal horn), or when they go backwards to the occipital cortex. So, if the initial portion of the optic radiation is respected, the VFD may tend to be congruous when the resection extends posteriorly. If optic nerve radiations are cut near the geniculate body where ipsilateral and contralateral fibres are mostly separated, the VFD may tend to be incongruous, even if the resection extends posteriorly. That could explain the absence of a correlation between the occurrence of congruity and the posterior extent of resection of the lateral temporal lobe.

Geniculocalcarine radiations maintain retinotopic organisation.<sup>16</sup> The representation of the vertical meridian lies farthest forward in the radiations and therefore makes the largest excursion in the temporal lobe. This explains the predominance of paravertical defects after

surgical lesion of the optic radiation in the anterior part of the temporal lobe. The localisation of the optic radiation representing macular vision has been often debated. Spalding<sup>16</sup> concluded that the fibres related to central vision lie on the lateral aspect of the radiation and that the fibres related to peripheral vision lie on the medial aspect, tending to congregate at its upper and lower margins. In contrast, Van Buren and Baldwin,<sup>4</sup> later confirmed by Marino and Rasmussen,<sup>9</sup> found that macular representation in Meyer's loop lies medial to that of the peripheral retina. Our study does not help to clarify this point, but we confirm that there is a contiguity of the representation of adjacent radial sectors of the peripheral field in optic nerve radiations. There is no separation by the optic nerve radiations representing the macular fibres of those representing the upper and lower quadrants of the visual field.

In our series, the VFDs did not affect visual acuity and were not considered troublesome or disabling by patients, which is coherent with the literature data,<sup>1 4 8 9 12 20 21</sup> whereas VFDs involving the lower quadrants tend to inconvenience the patients.<sup>22</sup>

The study of VFDs with automated perimetry after well defined temporal lobe resections by postoperative MRI allows us to refine knowledge on the architecture of the visual pathways, in particular the anterior limit of the temporal loop of the optic nerve radiations. Indeed, neurologists and surgeons must tend to minimise the complications, especially VFDs, without reducing the efficacy of this technique, which must remain the priority.

- 1 Tecoma ES, Laxer KD, Barbaro NM, et al. Frequency and characteristics of visual field deficits after surgery for mesial temporal sclerosis. *Neurology* 1993;43:1235-8.
- 2 Katz A, Awad IA, Kong AK, et al. Extent of resection in temporal lobectomy for epilepsy II. Memory changes and neurologic complications. *Epilepsia* 1989;30:763-71.
- 3 Meyer A. The connections of the occipital lobes and the present status of the cerebral visual affections. *Trans Assoc Am Phys* 1907;22:7-16.
- 4 Van Buren JM, Baldwin M. The architecture of the optic radiation in the temporal lobe of man. *Brain* 1958;81:15-40.
- 5 Awad IA. Anatomic considerations in temporal lobe surgery. In: Hans Lüders, ed. *Epilepsy surgery*. New York: Raven Press, 1991:547-58.
- 6 Talairach J, Tournoux P. *Co-planar stereotaxic atlas of the human brain. 3-Dimensional proportional system: An approach to cerebral imaging*. Stuttgart: Georg Thieme Verlag, 1988.
- 7 Engel J Jr, Van Ness PC, Rasmussen T, et al. Outcome with respect to epileptic seizures. In: Engel J Jr, ed. *Surgical treatment of the epilepsies*. 2nd ed. New York: Raven Press, 1993:609-21.
- 8 Jensen I, Seedorff HH. Temporal lobe epilepsy and neuro-ophthalmology: ophthalmological findings in 74 temporal lobe resected patients. *Acta Ophthalmol* 1976;54:827-41.
- 9 Marino R Jr, Rasmussen T. Visual field changes after temporal lobectomy in man. *Neurology* 1968;18:825-35.
- 10 Jensen I. Temporal lobe surgery around the world. *Acta Neurol Scand* 1975;52:354-73.
- 11 Guillaume J, Mazard G. Indications et résultats du traitement chirurgical des épilepsies temporales. *Sem Hop* 1956;32/2:2013-18.
- 12 Falconer MA, Wilson JL. Visual field changes following anterior temporal lobectomy: their significance in relation to Meyer's loop of the optic radiation. *Brain* 1958;81:1-14.
- 13 Hughes TS, Abou-Khalil B, Lavin PJM, et al. Visual field defects after temporal lobe resection. *Neurology* 1999;53:167-72.
- 14 Babb TL, Wilson CL, Crandall PH. Asymmetry and ventral course of the human geniculostriate pathway as determined by hippocampal visual evoked potentials and subsequent visual field defects after temporal lobectomy. *Exp Brain Res* 1982;47:317-28.

- 15 Behrens E, Schramm J, Zentner J, *et al.* Surgical and neurological complications in a series of 708 epilepsy surgery procedures. *Neurosurgery* 1997;41:1–10.
- 16 Spalding JMK. Wounds of visual pathway. Part I: The visual radiation. *J Neurol Neurosurg Psychiatry* 1952;15:99–109.
- 17 Walsh FB, Hoyt WF. Anatomy and physiology of the optic radiations (the geniculocalcarine tract). In: Miller NR, ed. *Clinical neuro-ophthalmology*. 4th ed. Baltimore/London: Williams and Wilkins, 1982:79–137.
- 18 Rasmussen T. Surgical treatment of patients with complex partial seizures. In: Penry JK, Daly DD, ed. *Advances in neurology*. Vol 11. New York: Raven Press, 1975:415–49.
- 19 Ebeling U, Reulen H-J. Neurosurgical topography of the optic radiation in the temporal lobe. *Acta Neurochir* 1988;92:29–36.
- 20 Wyllie E, Lüders H, Morris H, *et al.* Clinical outcome after complete or partial cortical resection for intractable epilepsy. *Neurology* 1987;37:1634–41.
- 21 Pilcher W, Roberts DW, Flanigin HF, *et al.* Complications of epilepsy surgery. In: Engel J Jr, ed. *Surgical treatment of epilepsies*. 2nd ed. New York: Raven Press, 1993: 565–81.
- 22 Jacobson DM. The localizing value of a quadrantanopia. *Arch Neurol* 1997;54:401–4.